

# Progression to Severe Retinopathy Predicted by Retinal Vessel Diameter Between 31 and 34 Weeks of Postconception Age

Michael P. Rabinowitz, MD; Juan E. Grunwald, MD; Karen A. Karp, BSN; Graham E. Quinn, MD, MSCE; Gui-shuang Ying, PhD; Monte D. Mills, MD

**Objective:** To assess the predictive value of early retinal vascular diameter measurements for the development of severe retinopathy of prematurity (ROP) in high-risk preterm infants.

**Methods:** Digital fundus images were taken of 78 eyes at risk for ROP with a noncontact camera during fundoscopic examination when infants were 31 to 34 weeks of postconception age. Vessel diameters were measured for the major superior and inferior temporal arteries and veins with the use of VesselMap software. Mean vessel diameters from eyes that developed severe ROP requiring treatment were compared with those that developed less severe ROP not requiring treatment or no ROP.

**Results:** All 4 major temporal retinal vessels showed significantly larger average diameters in the group of eyes that developed severe ROP requiring treatment. Multivariate analysis adjusted by birth weight, gestational age, and chronologic age showed similar results. Early retinal vessel diameter measurements showed good predictive value for the progression to severe ROP requiring treatment (area under the receiver operating characteristic curve, 0.75-0.94).

**Conclusions:** At 31 to 34 weeks of postconception age, average retinal vessel diameter measurements were significantly larger in infants who developed severe ROP requiring treatment than in infants who developed less severe ROP or no ROP.

*Arch Ophthalmol.* 2007;125(11):1495-1500

**R**ETINOPATHY OF PREMATURITY (ROP) is an eye disease characterized by retinal vascular immaturity followed by dilation and tortuosity.<sup>1-4</sup> Screening examinations begin at 31 weeks of postconception age (PCA),<sup>5-7</sup> manifestation of maximal ROP usually occurs at 36 to 38 weeks of PCA,<sup>1,8</sup> and treatment of ROP relies on a staging system<sup>9-13</sup> based on retinal vascular proliferation and diameter.<sup>7,14-17</sup> Despite what is often a long period of clinical observation between initial screening examination and development of maximum stage of ROP, to our knowledge no study to date has used early retinal vessel diameter measurements to predict eventual ROP clinical severity.

Photographic screening has been used to successfully diagnose and monitor other retinopathies, such as diabetic retinopathy.<sup>18-23</sup> It has provided similar validity in the diagnosis of ROP.<sup>24,25</sup> Recent studies have shown excellent sensitivities and specificities for the use of remote interpretation in the staging of severe ROP requiring treatment,<sup>25-29</sup> as well as for the automated detection of larger retinal vessels in eyes with

plus disease vs eyes without plus disease.<sup>30</sup> Our study attempts to evaluate the validity of using objective measurements of retinal vessel size from digital images taken during early retinal examination to predict the subsequent development of severe ROP requiring treatment.

In this study we report on quantitative analysis of retinal vessel diameters obtained from digital fundus images, taken from 31 to 34 weeks of PCA, of infants who are at risk for developing ROP. The goal of our investigation was to determine whether, early in the course of ROP progression and before disease outcome, infants who will later develop severe ROP requiring treatment have significantly different retinal vessel diameters from those who will develop less severe ROP or no ROP.

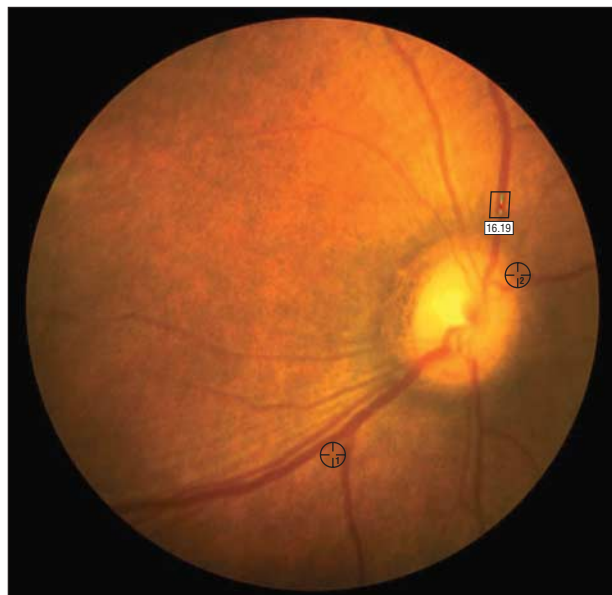
## METHODS

### PATIENT ENROLLMENT

Thirty-nine infants who were examined at The Children's Hospital of Philadelphia and Hospital of the University of Pennsylvania, who met criteria for ROP examination and whose parents provided informed consent, were en-

#### Author Affiliations:

Departments of Ophthalmology, Scheie Eye Institute/University of Pennsylvania, Philadelphia (Drs Rabinowitz, Grunwald, and Ying), and The Children's Hospital of Philadelphia (Ms Karp and Drs Quinn and Mills).



**Figure 1.** Fundus photograph assessed by VesselMap semiautomated software. Rectangle shows measured segments. Circles represent reference points by which software overlaps multiple images.

rolled between April 1, 2005, and September 30, 2006. All infants had a birth weight of 1250 g or less and a gestational age of 30 weeks or less. Infants were excluded if they had structural or congenital eye anomalies, were too medically unstable to undergo examination, or had previously been diagnosed as having ROP and treated for it.

This study was approved by the institutional review boards at the University of Pennsylvania Health System and The Children's Hospital of Philadelphia.

### ROP EXAMINATION AND DIGITAL IMAGING

Each enrolled infant underwent dilated fundus examination with indirect ophthalmoscopy and digital imaging of the fundus at an examination between 31 and 34 weeks of PCA. Bedside examinations were performed by an attending pediatric ophthalmologist in the neonatal intensive care unit. Digital fundus images were taken with a noncontact camera (model NM200D; NIDEK Co Ltd, Fremont, California). Each infant had as many images taken as could be obtained during the limited amount of time preceding indirect ophthalmoscopy, with an average of 8 images per eye (SD, 3.5). Patients then underwent successive imaging and indirect ophthalmoscopy every 1 to 2 weeks, as clinically indicated according to established protocols,<sup>6-8,31</sup> until the retinal vasculature matured, ROP regressed, or serious ROP was treated. The maximum stage of ROP and treatment status for each eye were recorded, and eyes were classified into 2 groups. One group contained eyes with severe ROP requiring treatment, meeting the following criteria: (1) any stage, zone 1 or 2, with plus disease, (2) stage 3, zone 1 or 2, with pre-plus disease, or (3) stage 2, zone 1 or 2, with pre-plus disease and the paired eye meeting criterion 1 or 2. The other group included eyes with less severe ROP (stage 1, 2, or 3 with neither plus disease nor a paired eye reaching treatment threshold) and eyes with no ROP, none of which required treatment.

### IMAGE SELECTION

All fundus images taken between 31 and less than 34 weeks of PCA were evaluated. Five infants had second examinations dur-

ing this period; images from the second examination were chosen and uploaded in these instances, as these images were of higher quality than images from the previous examination. Quality image grading logs were created to standardize the quality of the images, and each image was graded on a scale from 0 to 3, with 3 being the highest quality. Up to 3 of the highest-quality images from each eye of each infant were selected for vessel measurement. If fewer than 3 images of an eye were of high enough quality to take vessel measurements, fewer images of that eye were analyzed.

### VESSEL DIAMETER MEASUREMENT

One grader (M.P.R.), masked to ROP outcome, assessed the images by means of VesselMap semiautomated software (IMEDOS GmbH, Weimar, Germany) at the Scheie Eye Institute in Philadelphia. This program measures retinal vessel diameters on digital photographs, using arbitrary units (AU), by creating brightness indexes perpendicular to vessel lengths. Vascular width is thereby computed as wall-to-wall vessel distance.<sup>32</sup> Vessel widths were measured distant from vascular bifurcations and within 1 optic disc diameter of the disc itself. As multiple images (up to 3 images per eye) of each vessel were selected for measurement, 2 reference points were identified on each matching image, allowing for the overlap of identical images and the measurement of the same point on the same vessel with the use of numerous images (**Figure 1**).

### STATISTICAL ANALYSIS

For each image of analyzable quality, vessel diameter measurements were taken from the inferior temporal artery (ITA), superior temporal artery (STA), inferior temporal vein (ITV), and superior temporal vein (STV). Mean artery measurements (average of ITA and STA diameters) and mean vein measurements (average of ITV and STV diameters) were calculated for each image. The averages from multiple images of each eye were recorded as ITA, STA, mean artery, ITV, STV, and mean vein measurements for data analysis.

For ITA, STA, mean artery, ITV, STV, and mean vein measurements, 2-group *t* tests were used to compare mean vessel diameters between the group of eyes that later developed severe ROP requiring treatment and the group that later developed less severe ROP or no ROP. Therefore, 6 vessel diameter comparisons were made between the ROP groups. The conservative Bonferroni approach to multiple comparisons was applied, and comparisons associated with a 2-sided *P* value of .05 or less ( $<.008$ ) were determined to be statistically significant. The correlation from paired eyes of the same infant was adjusted by using generalized estimating equations. Further comparisons between groups were made through multivariate regression analysis to adjust for the effects of birth weight, gestational age (GA), and chronologic age at the date of the photographs (CA) on vessel diameter. To evaluate how the vessel diameter measurements predicted subsequent development of severe ROP requiring treatment, we performed receiver operating characteristic (ROC) analysis. For each vessel measurement, the area under the ROC curve and its 95% confidence interval were calculated through nonparametric ROC analysis in STATA version 7.0 (STATA Corp, College Station, Texas).

To evaluate grade-regrade reliability, a random sample of images from 14 eyes (6 that developed severe ROP requiring treatment and 8 that developed less severe ROP or no ROP) were remasked and reanalyzed by the same masked grader (M.P.R.) 2 months after initial analysis. The grade-regrade reliability of vessel diameter measurements was evaluated through paired *t* tests and Bland-Altman plots.

## RESULTS

Thirty-nine infants (78 eyes) were enrolled in this study; 21 (54%) were male, 22 (56%) were African American, and 15 (38%) were white. The mean±SD birth weight of enrolled infants was 824±172 g, with a median of 795 g (range, 504-1220 g). Mean GA was 25.6±1.28 weeks, with a median of 25.5 weeks (range, 23-29 weeks). Mean PCA at date of photographs was 32.8±0.92 weeks, with a median of 33.3 weeks (range, 30.0-33.9 weeks). Mean CA was 51.0±10.6 days, with a median of 51.0 days (range, 28-72 days). Infants who developed severe ROP requiring treatment had significantly lower average birth weight, GA, and CA than infants who developed less severe ROP or no ROP. There were no statistical differences in sex, race, or PCA at the date of the photographs between groups (**Table 1**).

Eighteen eyes of 9 infants developed severe ROP requiring treatment; mean PCA at worst stage was 35.4±2.8 weeks, and mean length of time between date of photographs and date of maximum stage of ROP was 2.4±2.8 weeks. Thirty-six eyes of 18 infants developed less severe ROP not requiring treatment; mean PCA at worst stage was 36.2±2.5 weeks, and mean length of time between date of photographs and date of maximum stage of ROP was 3.2±2.8 weeks. Twenty-four eyes of 12 patients did not develop any ROP.

Digital fundus images obtained from 78 eyes of 39 infants were analyzed. Poor image quality prevented vessel measurement in 59 (24%) analyzed photographs, representing 37 eyes. Of all 78 eyes studied, 1 or more vessels could not be measured in 37 eyes (47%), and there were no vessel measurements in 6 eyes (8%). Vessel measurements could be performed in 54 eyes (69%) for ITA, 57 eyes (73%) for STA, 66 eyes (85%) for ITV, and 65 eyes (83%) for STV.

On average, the group of eyes that later developed severe ROP requiring treatment had significantly larger mean vessel diameters for ITA (mean ± SE: 146.9±6.5 AU vs 108.8±3.6 AU,  $P < .001$ ), STA (138.9±6.3 AU vs 116.2±5.1 AU,  $P = .005$ ), and mean artery (141.7±4.4 AU vs 112.6±3.4 AU,  $P < .001$ ) measurements than the group of eyes that later developed less severe ROP or no ROP (**Figures 2A-C**). Veins showed similarly significant differences between groups, as ITV (206.4±6.6 AU vs 170.4±3.9 AU,  $P < .001$ ), STV (194.6±6.8 AU vs 167.8±4.8 AU,  $P = .001$ ), and mean vein (201.8±6.3 AU vs 169.7±3.5 AU,  $P < .001$ ) measurements were also larger in the group of eyes that later developed severe ROP requiring treatment (**Figures 2D-F**). All of these differences were still significant after Bonferroni correction for multiple comparisons, as the  $P$  values associated with these differences were all less than .008. Multivariate adjustment by birth weight, GA, and CA had minimal effect on the differences of mean vessel diameter measurements between groups (**Table 2**).

There was, however, overlap in arterial diameters between individual eyes that went on to develop severe ROP and those that did not (**Figure 2**). Using the lowest arterial diameter measurements in the severe ROP group as arterial diameter cutoff points (113.9 AU for ITA, 105.7

**Table 1. Characteristics of Infants Who Developed Severe ROP Requiring Treatment vs Less Severe ROP Not Requiring Treatment or No ROP<sup>a</sup>**

Characteristic	Less Severe or No ROP (n = 30)	ROP Requiring Treatment (n = 9)	P Value <sup>b</sup>
Sex, No. (%)			.71
Male	17 (57)	4 (44)	
Female	13 (43)	5 (56)	
Race, No. (%)			.21
African American	19 (63)	3 (33)	
White	9 (30)	6 (67)	
African American-Hispanic	1 (3)	0	
Hispanic	1 (3)	0	
Birth weight, g, mean (SE)	858 (32.1)	710 (32.5)	.02
GA, wk, mean (SE)	25.9 (0.22)	24.5 (0.33)	.002
PCA, wk, mean (SE)	32.8 (0.18)	33.0 (0.23)	.53
CA, d, mean (SE)	48.3 (1.74)	60.1 (3.12)	.002

Abbreviations: CA, chronologic age at date of photographs; GA, gestational age; PCA, postconception age at date of photographs; ROP, retinopathy of prematurity.

<sup>a</sup>In all cases, infants had the same ROP status in both eyes.

<sup>b</sup>Fisher exact test for comparison of proportions and 2-group  $t$  test for comparison of means.

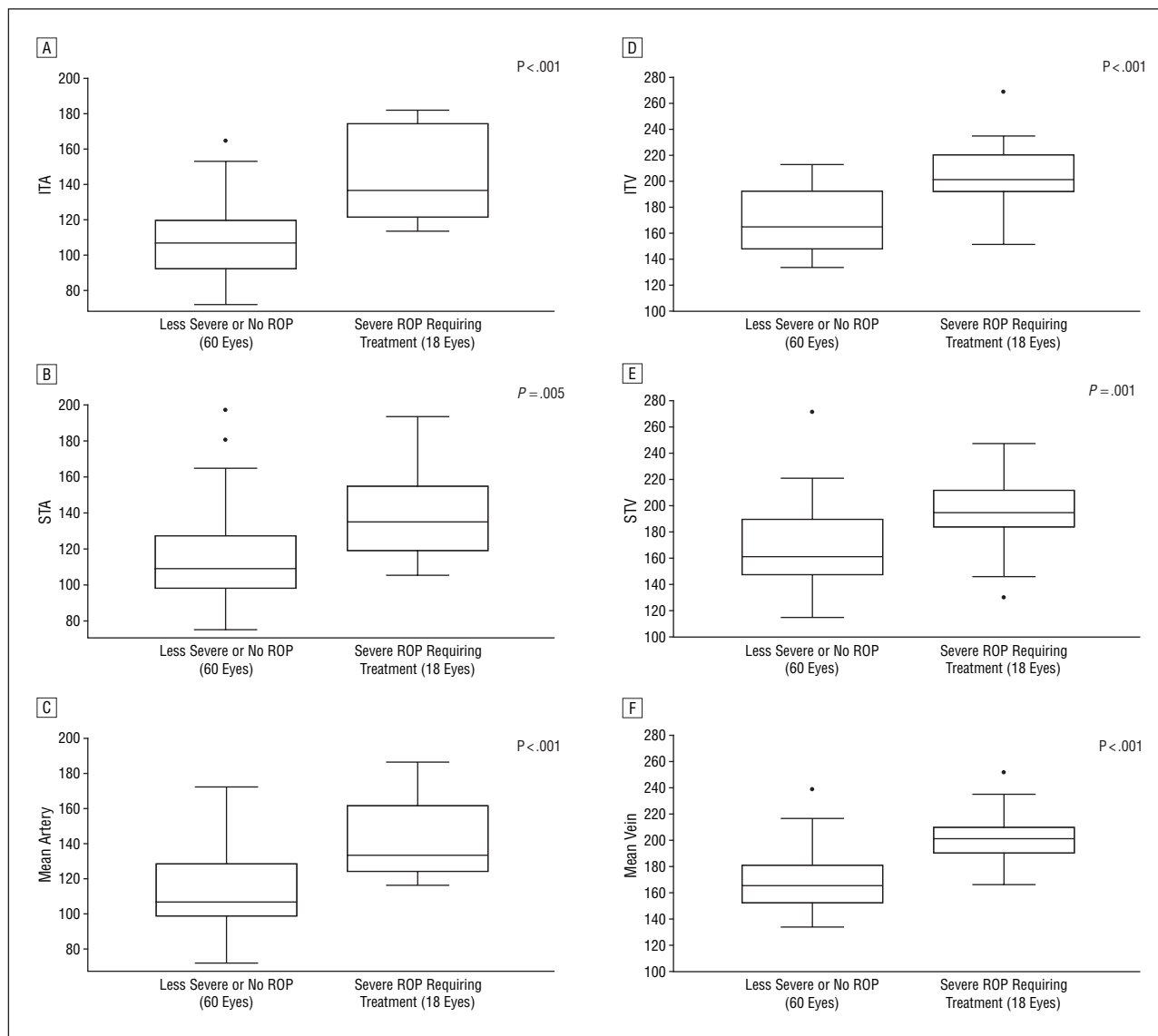
AU for STA, and 116.8 AU for mean artery) provided specificities of 40% for STA, 63% for ITA, and 63% for mean artery diameter measurements for the prediction of progression to less severe ROP not requiring treatment or no ROP.

The ROC analyses showed that vessel diameter measurements of all 4 major temporal vessels, mean artery measurements, and mean vein measurements could predict the subsequent development of severe ROP requiring treatment. The areas under the ROC curves (95% confidence intervals) were 0.94 (0.87-1.00) for ITA, 0.80 (0.65-0.96) for STA, and 0.93 (0.84-1.00) for mean artery measurements. The areas under the ROC curves were 0.91 (0.81-1.00) for ITV, 0.75 (0.54-0.97) for STV, and 0.87 (0.75-1.00) for mean vein measurements. There were no statistically significant differences in areas under the ROC curves between any pair of measures.

Grade-regrade comparisons were based on 11 images from 9 eyes for ITA, 14 images from 8 eyes for STA, 24 images from 13 eyes for ITV, and 20 images from 12 eyes for STV, and showed high grade-regrade reliability. There were no statistically significant differences in any of the vessel diameters between grade and regrade data, and confidence limits of grade-regrade differences for each of the 4 vessels were all within 15 AU (9.1 AU for ITA, 13.1 AU for STA, 14.9 AU for ITV, and 10.2 AU for STV). As grade-regrade reliability was similar for all measured vessels, a representative Bland-Altman plot of the grade-regrade agreements for STV was chosen (**Figure 3**).

## COMMENT

To assess the predictive value of very early retinal vasculature diameters for later development of ROP, major temporal vessel diameters measured between 31 and 34



**Figure 2.** Box plots comparing the distribution of inferior temporal artery (ITA), superior temporal artery (STA), mean artery, inferior temporal vein (ITV), superior temporal vein (STV), and mean vein measurements between eyes that developed severe retinopathy of prematurity (ROP) requiring treatment and eyes that developed less severe ROP not requiring treatment or no ROP. Each box plot includes the upper extreme (whisker, excluding outliers indicated as dots outside the box), upper quartile (upper portion of box), median (horizontal line in box), lower quartile (lower portion of box), and lower extreme (whisker). All values are in arbitrary units.

weeks of PCA were compared between eyes that later developed severe ROP requiring treatment and those that later developed less severe ROP not requiring treatment or no ROP. Each of the 4 vessels, as well as mean artery and mean vein measurements, had significantly larger average diameters in the group of eyes that later developed severe ROP requiring treatment. Multivariate analysis showed that vessel diameter differences between groups were independent of infant birth weight, GA, and CA. Furthermore, ROC analysis suggested that retinal vascular diameter measurements very early in the course of ROP evaluation may provide information regarding ROP course and final outcome.

However, temporal vessel diameter in an individual eye does not necessarily predict later development of severe ROP in that eye. Examination of Figure 2 shows substantial overlap between retinal vessel diameters of in-

dividual eyes that will progress and require treatment and individual eyes that will not. This is especially true for veins. However, very low early arterial diameter measurements do in fact seem predictive of later development of less severe ROP or no ROP in individual eyes, since no eyes with retinal vessel diameters less than 113.9 AU for ITA, 105.7 AU for STA, and 116.8 AU for mean artery went on to develop severe manifestations of disease. The value of these measures has yet to be proven in clinical practice.

Screening for ROP usually begins at 31 weeks of PCA,<sup>5-7</sup> with maximum stage of ROP usually occurring at 36 to 38 weeks of PCA.<sup>1,8</sup> This may result in 7 weeks or more of clinical observation before the maximum stage of ROP is observed. The majority of eyes of at-risk infants do not develop severe ROP requiring treatment.<sup>33</sup> Accurate prediction of progression to less severe ROP may help re-

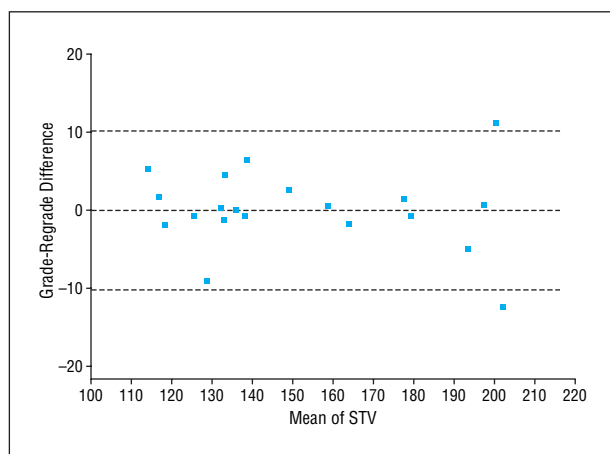
**Table 2. Vessel Measures in Eyes That Developed Severe ROP Requiring Treatment vs Less Severe ROP Not Requiring Treatment or No ROP<sup>a</sup>**

Vessel Measures	Mean (SE)					
	Univariate Analysis			Multivariate Analysis <sup>b</sup>		
	Less Severe or No ROP (n = 60)	ROP Requiring Treatment (n = 18)	P Value	Less Severe or No ROP (n = 60)	ROP Requiring Treatment (n = 18)	P Value
ITA	109 (3.64)	147 (6.52)	<.001	111 (3.46)	142 (7.83)	<.001
STA	116 (5.14)	139 (6.29)	.005	116 (4.43)	140 (6.87)	.001
Mean artery	113 (3.41)	142 (4.36)	<.001	113 (3.13)	140 (4.44)	<.001
ITV	170 (3.85)	206 (6.63)	<.001	172 (3.64)	203 (6.12)	<.001
STV	168 (4.81)	195 (6.75)	.001	168 (4.46)	193 (7.89)	.005
Mean vein	170 (3.49)	202 (6.25)	<.001	170 (3.38)	200 (6.38)	<.001

Abbreviations: ITA, inferior temporal artery; ITV, inferior temporal vein; ROP, retinopathy of prematurity; STA, superior temporal artery; STV, superior temporal vein.

<sup>a</sup>Data are expressed in arbitrary units.

<sup>b</sup>Adjusted by birth weight, gestational age, and chronologic age at date of photographs.



**Figure 3.** Representative Bland-Altman plot for the grade-regrade agreement of superior temporal vein (STV) diameter measurements. Each point represents a measured value from an image. The middle dashed line represents the mean of the grade-regrade differences; solid line overlapping it represents the reference line with zero difference. The upper and lower dashed lines represent the mean  $\pm$  2 SDs of grade-regrade differences.

duce the number of eye examinations for those infants unlikely to develop severe manifestations of disease.

There are several limitations to this study. First, it was more difficult to obtain images in some infants than others. We were unable to obtain 3 images of high enough quality to analyze in every eye, and not every image had 4 measurable temporal vessels. Furthermore, the VesselMap software measured vessel diameters in arbitrary units, which cannot be easily compared with absolute measurements. However, our study was a comparison of vessel diameters between ROP outcome groups, and eyes in both groups were measured using the same protocol.

Finally, we defined ROP outcome groups on the basis of maximum clinical severity (severe ROP requiring treatment vs less severe ROP not requiring treatment or no ROP) rather than ROP stage. Our study was planned during a time when the Early Treatment of Retinopathy of Prematurity guidelines were evolving. As such, some

eyes were treated before they developed threshold ROP, and these eyes would have been excluded if we had established threshold disease as the study end point.

In summary, our study suggests that retinal vessel diameter measurements obtained at 31 to less than 34 weeks of PCA are larger, on average, in groups of high-risk infants who are more likely to develop severe ROP and require treatment. Furthermore, it seems that very small early arterial diameters may predict that an eye will progress to less severe ROP not requiring treatment or no ROP. Prospective studies further quantifying and qualifying the relationships between early retinal vasculature diameters and maximal ROP severity are needed to explore the full clinical potential of these findings.

**Submitted for Publication:** February 10, 2007; final revision received April 27, 2007; accepted May 1, 2007.

**Correspondence:** Monte D. Mills, MD, The Children's Hospital of Philadelphia, 3400 Civic Center Blvd, Philadelphia, PA 19104.

**Author Contributions:** Dr Mills, principal investigator, had full access to all the data in the study and takes responsibility for the integrity of the data and the accuracy of the data analysis.

**Funding/Support:** This study was supported by the Mabel E. Leslie Endowed Chair; The Children's Hospital of Philadelphia; Vivian S. Lasko Research Fund; and Nina C. Mackall Trust, Research to Prevent Blindness.

**Additional Contributions:** Image collection was performed by William Anninger, MD, at The Children's Hospital of Philadelphia.

## REFERENCES

- Palmer EA, Flynn JT, Hardy RJ, et al. Incidence and early course of retinopathy of prematurity: the Cryotherapy for Retinopathy of Prematurity Cooperative Group. *Ophthalmology*. 1991;98(11):1628-1640.
- Rechia FM, Capone A. Retinopathy of prematurity. In: Yanoff M, Duker JS, eds. *Ophthalmology*. 2nd ed. St Louis, MO: Mosby Inc; 2004:870-874.
- Rechia FM, Capone A. Contemporary understanding and management of retinopathy of prematurity. *Retina*. 2004;24(2):283-292.
- Tasman W, Patz A, McNamara JA, Kaiser RS, Trese MT, Smith BT. Retinopathy

- of prematurity: the life of a lifetime disease. *Am J Ophthalmol.* 2006;141(1):167-174.
5. Hardy RJ, Palmer EA, Schaffer DB, Phelps DL, Davis BR, Cooper CJ. Outcome-based management of retinopathy of prematurity: Multicenter Trial of Cryotherapy for Retinopathy of Prematurity Cooperative Group. *J AAPOS.* 1997;1(1):46-54.
  6. Section on Ophthalmology, American Academy of Pediatrics, American Academy of Ophthalmology, American Association for Pediatric Ophthalmology and Strabismus. Screening examination of premature infants for retinopathy of prematurity. *Pediatrics.* 2006;117(2):572-576.
  7. Reynolds JD, Dobson V, Quinn GE, et al; CRYO-ROP and LIGHT-ROP Cooperative Groups. Evidence-based screening criteria for retinopathy of prematurity: natural history data from the CRYO-ROP and LIGHT-ROP studies. *Arch Ophthalmol.* 2002;120(11):1470-1476.
  8. Cryotherapy for Retinopathy of Prematurity Cooperative Group. Multicenter trial of cryotherapy for retinopathy of prematurity: three-month outcome. *Arch Ophthalmol.* 1990;108(2):195-204.
  9. Ng EY, Connolly BP, McNamara JA, Regillo CD, Vander JF, Tasman W. A comparison of laser photocoagulation with cryotherapy for threshold retinopathy of prematurity at 10 years, part 1: visual function and structural outcome. *Ophthalmology.* 2002;109(5):928-934.
  10. Good WV; Early Treatment for Retinopathy of Prematurity Cooperative Group. Final results of the Early Treatment for Retinopathy of Prematurity (ETROP) randomized trial. *Trans Am Ophthalmol Soc.* 2004;102:233-248.
  11. Paysse EA, Lindsey JL, Coats DK, Contant CF Jr, Steinkuller PG. Therapeutic outcomes of cryotherapy versus transpupillary diode laser photocoagulation for threshold retinopathy of prematurity. *J AAPOS.* 1999;3(4):234-240.
  12. Cryotherapy for Retinopathy of Prematurity Cooperative Group. Multicenter trial of cryotherapy for retinopathy of prematurity: preliminary results. *Arch Ophthalmol.* 1988;106(4):471-479.
  13. Good WV; Early Treatment for Retinopathy of Prematurity Cooperative Group. The Early Treatment for Retinopathy of Prematurity Study: structural findings at age 2 years. *Br J Ophthalmol.* 2006;90(11):1378-1382.
  14. Good WV, Hardy RJ, Dobson V, et al; Early Treatment for Retinopathy of Prematurity Cooperative Group. The incidence and course of retinopathy of prematurity: findings from the Early Treatment for Retinopathy of Prematurity Study. *Pediatrics.* 2005;116(1):15-23.
  15. International Committee for the Classification of Retinopathy of Prematurity. The International Classification of Retinopathy of Prematurity revisited. *Arch Ophthalmol.* 2005;123(7):991-999.
  16. Hardy RJ, Palmer EA, Dobson V, et al; Cryotherapy for Retinopathy of Prematurity Cooperative Group. Risk analysis of prethreshold retinopathy of prematurity. *Arch Ophthalmol.* 2003;121(12):1697-1701.
  17. Patz A. New international classification of retinopathy of prematurity. *Pediatrics.* 1984;74(1):160-161.
  18. Kinyoun JL, Martin DC, Fujimoto WY, Leonetti DL. Ophthalmoscopy versus fundus photographs for detecting and grading diabetic retinopathy. *Invest Ophthalmol Vis Sci.* 1992;33(6):1888-1893.
  19. Klein R, Klein BE, Neider MW, Hubbard LD, Meuer SM, Brothers RJ. Diabetic retinopathy as detected using ophthalmoscopy, a nonmydriatic camera and a standard fundus camera. *Ophthalmology.* 1985;92(4):485-491.
  20. Lin DY, Blumenkranz MS, Brothers RJ, Grosvenor DM. The sensitivity and specificity of single-field nonmydriatic monochromatic digital fundus photography with remote image interpretation for diabetic retinopathy screening: a comparison with ophthalmoscopy and standardized mydriatic color photography. *Am J Ophthalmol.* 2002;134(2):204-213.
  21. Pugh JA, Jacobson JM, Van Heuven WA, et al. Screening for diabetic retinopathy: the wide-angle retinal camera. *Diabetes Care.* 1993;16(6):889-895.
  22. Fundus Photograph Reading Center Web site, Department of Ophthalmology and Visual Sciences, University of Wisconsin-Madison. <http://eyephoto.opth.wisc.edu/>. Accessed January 4, 2007.
  23. Williams GA, Scott IU, Haller JA, Maguire AM, Marcus D, McDonald HR. Single-field fundus photography for diabetic retinopathy screening. *Ophthalmology.* 2004;111(5):1055-1062.
  24. Roth DB, Morales D, Feuer WJ, Hess D, Johnson RA, Flynn JT. Screening for retinopathy of prematurity employing the RetCam 120: sensitivity and specificity. *Arch Ophthalmol.* 2001;119(2):268-272.
  25. Chiang MF, Starren J, Du YE, et al. Remote image based retinopathy of prematurity diagnosis: a receiver operating characteristic analysis of accuracy. *Br J Ophthalmol.* 2006;90(10):1292-1296.
  26. Ellis AL, Holmes JM, Astle WF, et al. Telemedicine approach to screening for severe retinopathy of prematurity: a pilot study. *Ophthalmology.* 2003;110(11):2113-2117.
  27. Wu C, Petersen RA, VanderVeen DK. RetCam imaging for retinopathy of prematurity screening. *J AAPOS.* 2006;10(2):107-111.
  28. Chiang MF, Keenan JD, Du YE, et al. Assessment of image-based technology: impact of referral cutoff on accuracy and reliability of remote retinopathy of prematurity diagnosis. *AMIA Annu Symp Proc.* 2005:126-130.
  29. Chiang MF, Keenan JD, Starren J, et al. Accuracy and reliability of remote retinopathy of prematurity diagnosis. *Arch Ophthalmol.* 2006;124(3):322-327.
  30. Gelman R, Martinez-Perez ME, Vanderveen DK, Moskowitz A, Fulton AB. Diagnosis of plus disease in retinopathy of prematurity using Retinal Image Multi-Scale Analysis. *Invest Ophthalmol Vis Sci.* 2005;46(12):4734-4738.
  31. Phelps DL; ETROP Cooperative Group. The Early Treatment for Retinopathy of Prematurity Study: better outcomes, changing strategy. *Pediatrics.* 2004;114(2):490-491.
  32. Metelitsina TI, Grunwald JE, DuPont JC, Ying GS, Liu C. Effect of Viagra on retinal vein diameter in AMD patients. *Exp Eye Res.* 2006;83(1):128-132.
  33. Hussain N, Clive J, Bhandari V. Current incidence of retinopathy of prematurity, 1989-1997. *Pediatrics.* 1999;104(3):e26. <http://pediatrics.aappublications.org/cgi/content/full/104/3/e26>. Accessed April 19, 2007.

#### From the Archives of the Archives

Holth believes that couching is indicated when the first eye has been lost from expulsive hemorrhage after extraction. Also, in certain incurably insane persons the operation may be done. Exceptionally, couching may be done because of a dense membranous cataract which cannot be discised with Knapp's knife and extraction is inadvisable.

**Reference:** Holth. May couching be indicated today? *Arch Ophthalmol.* 1902;31.