

Change in Distant Atrial Activation Patterns During Circumferential Pacemapping of Pulmonic Vein Ostium: Implications for Localizing Triggers for Atrial Fibrillation

Sanjay Dixit, Edward P. Gerstenfeld, Robert W. Rho, Vickas Patel, David J. Callans, and Francis E. Marchlinski

University of Pennsylvania Health System, Philadelphia, PA 19104, USA

Abstract. Introduction: Unique intracardiac activation patterns recorded from multipolar catheters in the coronary sinus (CS) and posteromedial right atrium (RA) when pacing from ostium (os) of each pulmonic vein (PV) can serve as template for determining PV of origin of atrial premature complexes. Development of an accurate template requires knowledge of variations in activation pattern during pacing from different aspects of same PV.

Methods: In 25 patients undergoing catheter ablation for AF, a decapolar Lasso mapping catheter was placed at PV os of interest and multipolar catheters were placed in CS and RA—medial to crista terminalis (CT). For each PV, pacing was performed from Lasso catheter poles 1 through 10. For each bipole paced, activation sequence in CS (proximal to distal & vice-versa) was assessed, activation time (pacing stimulus to earliest electrogram recorded in catheters in CS/along CT) was measured and difference (CS – CT time) was determined. Significant interpolar variation was defined as the difference between the shortest and longest CS – CT activation time of ≥ 25 msec when pacing from different bipoles of same PV.

Results: In 59 PVs [19 right superior (RS), 20 left superior (LS), 8 right inferior (RI) and 12 left inferior (LI)], 259 bipoles were paced (median of 4 bipoles/PV). During circumferential PV pacing activation sequence in CS catheter was distal to proximal in 84.4% left-sided PVs (LSPV and LIPV) and proximal to distal in 92.6% right-sided PVs (RSPV and RIPV) with no change in activation sequence observed during pacing from different bipoles in same PV. Significant interpolar variation was observed with circumferential pacing in 1 of 19 RSPV (5.3%), 2 of 20 LSPV (10%), 1 of 12 LIPV (8.3%) and none of RIPV.

Conclusion: Unique intracardiac activation patterns during ostial pacing from individual PV are not influenced by circumferential location of pacing site.

Key Words. localization, pace-map, pulmonary vein, atrial fibrillation, activation patterns

Introduction

Atrial fibrillation (AF) is often initiated by atrial premature complexes (APCs) [1]. In the majority

of cases, APCs initiating AF have been documented to arise from atrial muscle within or at the ostium (os) of one or more pulmonic veins (PV) [2,3]. Targeting the PV of origin is critical for successfully curing AF using catheter based radiofrequency ablation [4,5]. In a previous study we had shown that unique intracardiac activation patterns of multipolar catheters positioned in the coronary sinus (CS) and along the posteromedial right atrium (RA) are seen when individual PV os are paced and these activation patterns could serve as a template for determining the PV of origin of spontaneous APC(s) occurring in the electrophysiology laboratory [6]. However, in that study pace-mapping was performed from single sites at the os of each PV. It is possible that pacing from different aspects along the circumference of the same PV os may alter intracardiac activation patterns and this information is important in developing an accurate template for predicting the PV of origin of APC(s) using pace-mapping.

The objective of the study was to characterize and quantify variability, if any, in intracardiac activation patterns when pacing circumferentially from different sites along the ostium of individual Pulmonic Veins.

Methods

Twenty-five patients (mean age 54 ± 7 years) undergoing catheter ablation for AF participated in the study. All procedures followed the institutional guidelines of the University of Pennsylvania Health System. All antiarrhythmic drugs except

Address for correspondence: Francis E. Marchlinski, MD, 9 Founders Pavilion, Hospital of University of Pennsylvania, 3400 Spruce Street, Philadelphia, PA 19104. E-mail: francis.marchlinski@uphs.upenn.edu

Received 21 October 2002; accepted 14 January 2003

amiodarone were stopped five half-lives before the procedure. Amiodarone was stopped 2 weeks prior to the date of the procedure. Intravenous sedation was administered with midazolam and fentanyl. Under fluoroscopic guidance, two decapolar catheters with 5-mm electrodes and 2-mm inter-electrode spacing were placed in the CS (proximal electrode pair at the CS os) and posterior RA medial to the crista terminalis (CT) with the most distal electrode pair positioned in the superior vena cava. Using long introducer sheaths ($n = 2$; USCI Mullins), under fluoroscopic and intracardiac ultrasound (Acuson; AcuNav diagnostic ultrasound catheter) guidance, two serial transeptal punctures were made and the ablation catheter (CARTO-Biosense, Inc., Diamond Bar, CA, USA; 4-mm tip, 1-mm interelectrode spacing) as well as the decapolar Lasso mapping catheter (Webster, Inc., CA, USA; 15 mm circumference; 1–2 mm interelectrode spacing) were advanced into the LA.

Creation of LA Endocardial Shell and Defining the PV Os

Using the CARTO system, multiple points (range 104–220) were acquired during sinus rhythm in order to create a three-dimensional magnetic electro-anatomic map (MEAM) of the LA. Each PV

received a distinct tubular tag on the MEAM. The location of the PV(s) was confirmed by the following characteristics: (1) catheter tip beyond the LA endocardial shell on MEAM and beyond the cardiac silhouette on fluoroscopic image, and (2) loss of atrial electrograms. Also, the os of each PV was carefully defined by: (1) repeated reengagement of the PV with the Lasso catheter on fluoroscopy, (2) localization of the PV os on MEAM, (3) confirmation of ostial location of the Lasso mapping catheter by intracardiac ultrasound imaging and (4) recording of the characteristic intracardiac signals (atrial electrogram followed by sharp PV potential) indicating entry into the PV on the bipoles of the Lasso catheter (Fig. 1).

Circumferential PV Pace-Mapping

After the lasso catheter was adequately positioned at the PV os of interest, at twice the diastolic threshold via a programmable digital stimulator (Bloom Associates Ltd., Reading, PA, USA) at a cycle length of 500 or 600 msec, serially circumferential pacing was performed from poles 1 through 10 (5 bipoles: 1–2, 3–4, 5–6, 7–8 and 9–10) for 10–15 uninterrupted captured beats. All intracardiac bipolar electrograms were filtered at 30 to 500 Hz and recorded at a speed of 200 mm/sec

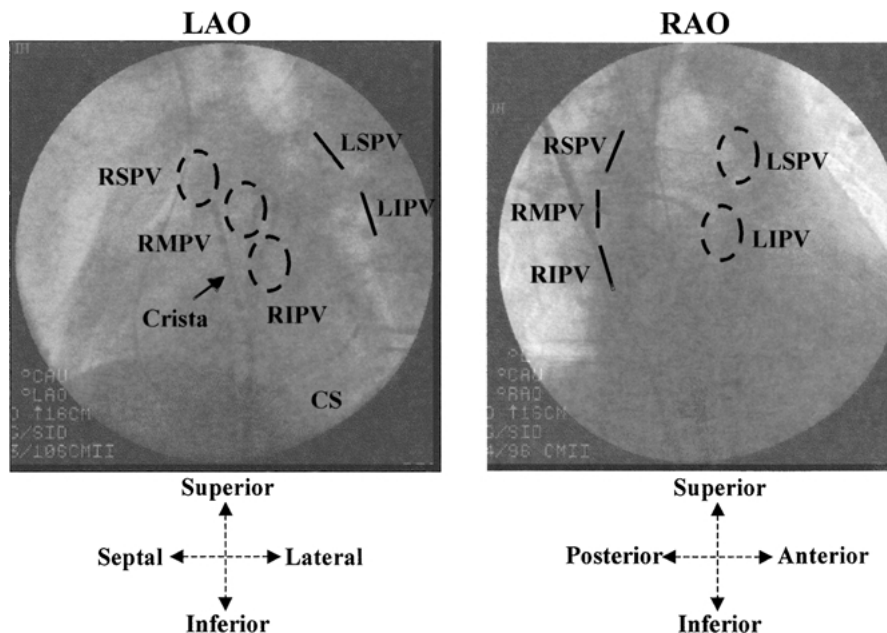


Fig. 1. Orthogonal fluoroscopic projections of the heart in the left anterior oblique (LAO) and right anterior oblique (RAO) projections. The right-sided pulmonary veins appear end-on in the LAO projections and the left-sided pulmonary veins appear end-on in the RAO projections and are shown as interrupted ovals and bars in the figure. In addition to the circumferential “Lasso” mapping catheter, also seen are the multipolar catheters in the coronary sinus (CS) and along the crista terminalis (CT). RSPV: right superior pulmonary vein, LSPV: left superior pulmonary vein, RMPV: right middle pulmonary vein, RIPV: right inferior pulmonary vein and LIPV: left inferior pulmonary vein. In this particular patient the Lasso catheter is located at the ostium of the RMPV.

on an electrophysiologic recording system (Prucka Engineering, Houston, TX, USA) and analyzed offline using digital calipers. For each Lasso bipole paced and successfully captured, the intracardiac recordings in the multipolar CS catheter were analyzed to determine the sequence of activation—distal to proximal or vice-versa. Also activation time (msec) from stimulus to the earliest electrogram recorded on the multipolar catheter in the CS and along the CT was measured and the difference between the onset of the earliest recording in the CS and the CT was determined (CS – CT time; msec). In order to quantify the variation during pace-mapping around the circumference of each PV os, after determining the CS – CT time at each bipole, the difference between bipoles demonstrating the shortest and longest CS – CT time was calculated. We define this as interpolar variation in CS – CT time. In a previous study, we have observed that when repeating intracardiac measurements there is an intraobserver variability of 4 msec and an interobserver variability of 8 msec, which would allow the maximum error to be 12 msec [6]. Since in assessing the CS – CT time, two intracardiac measurements were made, we define significant interpolar vari-

ation if the difference between the shortest and longest CS – CT activation time was ≥ 25 msec.

Overlap in Intracardiac Activation Patterns Between Pulmonic Veins

Because of time constraints, circumferential ostial pace-mapping could not be performed in all 4 PVs in all patients. However, in 18 patients (sub group of the original 25 patients), pace-mapping was performed from the PVs on the same side—left superior (LS) and left inferior (LI) in 11 patients and right superior (RS) and right inferior (RI) in 7 patients. In each pair of PVs on the same side the CS – CT activation time for all the bipoles pace-mapped was compared to determine if the numerical values crossed over between the ipsilateral superior and inferior PVs. We define this as “overlap” in CS – CT time between the same sided veins.

Statistical Analysis

Continuous measures are expressed as mean \pm SD and were compared with a *t* test for paired and unpaired data, as appropriate. A *p* value ≤ 0.05 was considered statistically significant.

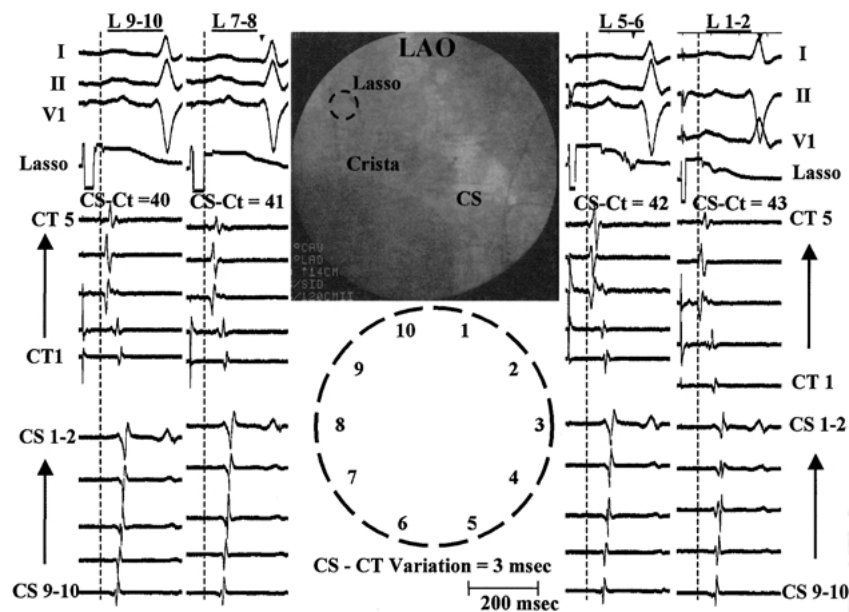


Fig. 2. A typical example of the activation pattern when pace-mapping (PM) is performed from right superior pulmonary vein (RSPV) ostium (os). The Lasso mapping catheter located at the os appears end-on in the left anterior oblique (LAO) projection. Bipole 1–2 is located superiorly and laterally in the PV and the rest follow in a clockwise manner. PM was successfully performed from bipoles 1–2, 5–6, 7–8 and 9–10. Bipole 3–4 did not capture. In each PM it can be appreciated that sequence of activation of multipolar catheter in coronary sinus (CS) is proximal to distal and activation of multipolar catheter adjacent to crista terminalis (CT) precedes CS activation in each panel. For this example, CS – CT time ranges from the 40 msec to 43 msec so that interpolar variation in CS – CT time was 3 msec. In each panel orientation of electrograms from top to bottom are: surface ECG leads I, II and V1, Lasso catheter bipole pace-mapped, recordings from multipolar catheter adjacent to CT (CT1 at the junction of right atrium and superior vena cava) and recordings from multipolar catheter in the CS (CS 9–10 located at the ostium of coronary sinus).

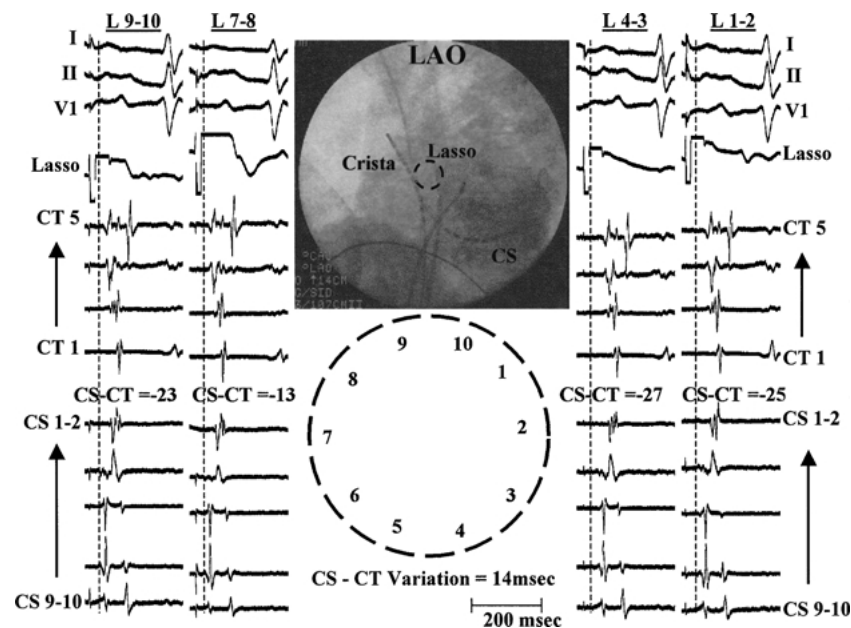


Fig. 3. A typical example of the activation pattern when pace-mapping (PM) is performed from right inferior pulmonary vein (RIPV) ostium (Os). The Lasso mapping catheter located at the Os appears end-on in the left anterior oblique (LAO) projection. Bipole 1-2 is located superiorly and laterally in the PV and the rest follow in a clockwise manner: PM was successfully performed from bipoles 1-2, 3-4, 7-8 and 9-10. Bipole 5-6 did not capture. In each PM it can be appreciated that sequence of activation of multipolar catheter in coronary sinus (CS) is proximal to distal and activation of multipolar catheter adjacent to crista terminalis (CT) follows CS activation in each panel. For this example, CS - CT time ranges from the -13 msec to -27 msec so that inter-polar variation in CS - CT time is 14 msec. In each panel orientation of electrograms from top to bottom are: surface ECG leads I, II and VI, Lasso catheter bipole pace-mapped, recordings from multipolar catheter adjacent to CT (CT1 at the junction of right atrium and superior vena cava) and recordings from multipolar catheter in the CS (CS 9-10 located at the ostium of coronary sinus).

Results

Pace-mapping was successfully performed in 59 PVs. This included 19 RSPV, 20 LSPV, 8 RIPV and 12 LIPV. In the 59 PVs studied, 259 sites (bipoles) were captured accounting for a median of 4 sites (bipoles) out of 5 sites (bipoles)/PV that were pace-mapped in a circumferential distribution.

Activation Sequence in CS

The activation sequence in the multipolar CS catheter was distal to proximal when pace-mapping along the ostial circumference of the majority of (27 of 32; 84.4%) left-sided PVs (LSPV and LIPV). On the other hand, in the majority of (25 of 27; 92.6%) right-sided PVs (RSPV and RIPV), circumferential pace-mapping demonstrated proximal to distal activation along the CS. In the remaining PVs simultaneous activation of multiple poles occurred which prevented the determination of a clear pattern of hierarchical activation from distal to proximal poles and/or vice-versa. Importantly, in none of the PVs (both left and right sided) was a change in the CS activation sequence observed during pace-mapping from dif-

ferent bipoles along the circumference of the same PV (Figs. 2-5).

Difference in Activation Time to CS and CT (CS - CT)

The difference in the earliest activation time to the multipolar catheters in the CS and along the CT (CS - CT) was distinct between the right and the left sided PVs (see Table 1). For the RSPV, CS - CT was 37.5 ± 12.4 msec (Range 14 to 70 msec), for the RIPV CS - CT was 21.7 ± 24.8 msec (Range -27 to 64 msec), for the LSPV CS - CT was 4.9 ± 14.6 msec (Range -27 to 34 msec) and for the LIPV CS - CT was -10.3 ± 9.8 msec (Range -29 to 12 msec). Thus, as a general rule the CT activates before the CS for the right-sided PVs and the CS activates before the CT for the left-sided PVs. Also the activation time to the CT is shorter for the RSPV compared with RIPV accounting for a higher CS - CT activation time (37.5 ± 12.4 vs 21.7 ± 24.8 msec; $p < 0.001$). For the left-sided PVs, the activation time to the CS was shorter when pace-mapping from the LIPV as compared with LSPV, resulting in a shorter CS - CT activation time (-10.3 ± 9.8 vs 4.9 ± 14.6 msec; $p < 0.001$).

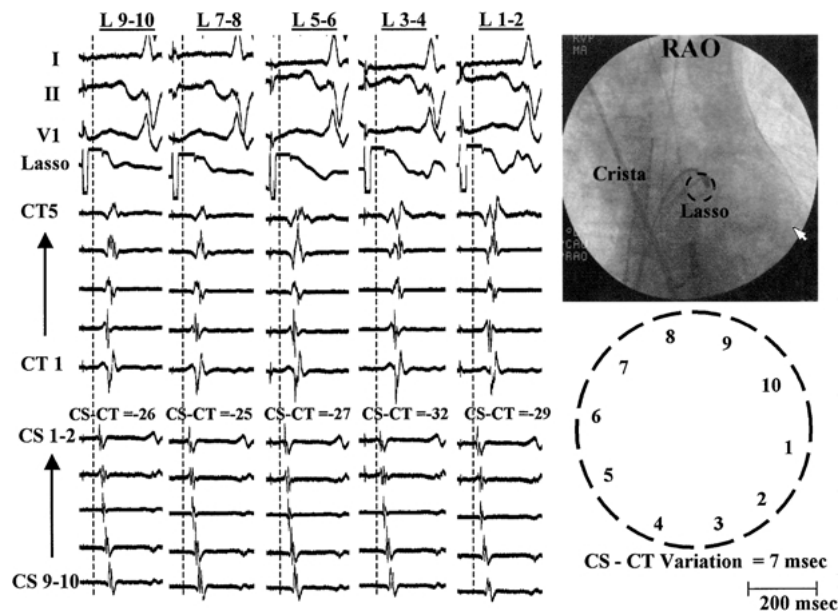


Fig. 4. A typical example of the activation pattern when pace-mapping (PM) is performed from left inferior pulmonary vein (LIPV) ostium (Os). The Lasso mapping catheter located at the Os appears end-on in the right anterior oblique (RAO) projection. Bipole 1–2 is located inferiorly and anteriorly in the PV and the rest follow in a clockwise manner. PM was successfully performed all bipoles (1–2, 3–4, 5–6, 7–8 and 9–10). In each PM it can be appreciated that sequence of activation of multipolar catheter in coronary sinus (CS) is distal to proximal and activation of multipolar catheter adjacent to crista terminalis (CT) follows CS activation in each panel. For this example, CS – CT time ranges from the –25 msec to –32 msec so that inter-polar variation in CS – CT time is 7 msec. In each panel orientation of electrograms from top to bottom are: surface ECG leads I, II and V1, Lasso catheter bipole pace-mapped, recordings from multipolar catheter adjacent to CT (CT1 at the junction of right atrium and superior vena cava) and recordings from multipolar catheter in the CS (CS 9–10 located at the ostium of coronary sinus).

Inter-polar Variation in CS – CT During Circumferential PV Pace-Mapping

The variation in the CS – CT time during individual circumferential PV pace-mapping was: 8.3 ± 7.6 msec (Range 0 to 30 msec) for RSPV, 11.8 ± 6.6 msec (Range 3 to 23 msec) for RIPV, 14.2 ± 7.3 msec (Range 5 to 28 msec) for LSPV and 9.6 ± 7.9 msec (Range 0 to 30 msec) for LIPV. The mean inter-polar variation in CS – CT was higher for the LSPV as compared with RSPV ($p = 0.02$) but was comparable to the mean inter-polar variation in the LIPV ($p = NS$). More importantly, significant inter-polar variation (≥ 25 msec) was observed during circumferential pace-mapping in only 1 of 19 RSPV (5.3%), none of the 8 RIPV, 2 of 20 LSPV (10%) and 1 of 12 LIPV (8.3%) (Table 1).

Overlap in CS – CT During Circumferential Pace-Mapping of Same Sided PVs

In the subgroup analysis of 18 patients in whom circumferential pace-mapping was successfully performed from same sided PVs (LSPV/LIPV in 11 patients and RSPV/RIPV in 7 patients), overlap in the CS – CT time was seen in 3 of 11 left sided PVs (27.2%) and 5 of 7 right sided PVs (71.4%).

Discussion

In this study we have shown that pace-mapping from around the os of PVs manifest distinct intracardiac AP as recorded by multipolar catheters placed in the CS and along the CT in RA that can help in localization. Unique to the study is the observation that the intracardiac activation patterns in the majority of PVs remain consistent with insignificant inter-polar variation despite pace-mapping circumferentially at the os of individual PV.

Based on the seminal studies from the group in Bordeaux and observation of other investigators, it is now widely accepted that AF is frequently initiated by APC(s) originating from one or more PVs [1–5,7]. Targeting the PV of origin of APC(s) has been shown to cure AF. This has resulted in renewed interest in developing accurate strategies for localizing the vein of origin of ectopic activity. Pace-mapping to mimic intracardiac activation patterns of both atrial and ventricular arrhythmias has been successfully used in facilitating ablation [6,8,9]. Unique activation patterns (sequence of activation/earliest activation) in multipolar catheters placed in strategic locations (in the RA, in the CS, at the His-Bundle, in the lower

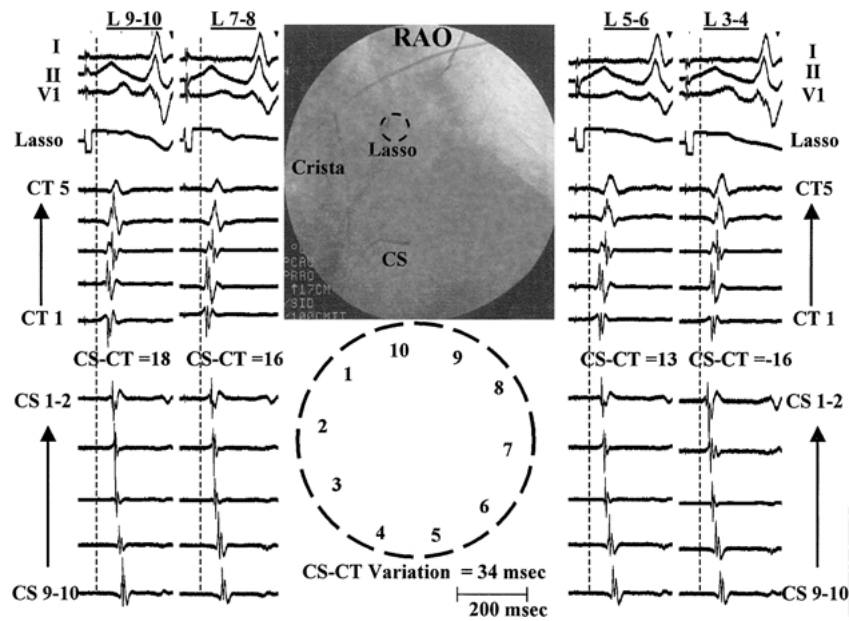


Fig. 5. This is a typical example of the activation pattern when pace-mapping (PM) is performed from left superior pulmonary vein (LSPV) ostium (Os). The Lasso mapping catheter located at the os appears end-on in the right anterior oblique (RAO) projection. Bipole 1-2 is located superiorly and posteriorly in the PV and the rest follow in a counter-clockwise manner. PM was successfully performed from bipoles 3-4, 5-6, 7-8 and 9-10. Bipole 1-2 did not capture. In each PM it can be appreciated that sequence of activation of multipolar catheter in coronary sinus (CS) is distal to proximal and activation of multipolar catheter adjacent to crista terminalis (CT) precedes CS activation all but one panel (except when PM bipole 3-4). For this example, CS – CT time ranges from the –16 msec to 18 msec so that interpolar variation in CS – CT time is 34 msec. In each panel orientation of electrograms from top to bottom are: surface ECG leads I, II and V1, Lasso catheter bipole pace-mapped, recordings from multipolar catheter adjacent to CT (CT1 at the junction of right atrium and superior vena cava) and recordings from multipolar catheter in the CS (CS 9-10 located at the ostium of coronary sinus).

esophagus) have been shown to help in localizing the vein of origin of spontaneous APC(s) in patients undergoing AF ablation [5,10]. In a previous study by pace-mapping from all the 4 PVs, using multipolar catheters placed in the CS and along the posteromedial RA adjacent to the CT, we had developed criteria that allowed us to successfully identify the vein of origin of spontaneous APCs. These criteria were based on pace-mapping from single sites at the os of each PV [6]. Whether intracardiac activation patterns can be influenced by the site of pacing around the circumference of the PV was not addressed in that study. This is especially important to know because as has been

shown by Hocini and colleagues, APCs can result from more than one location in the same PV(s) [11]. However in their study, the authors do not report the influence of the different sites of origin of APCs on intracardiac activation patterns once they exited out of the vein. Our observations from the current study, would suggest that in the majority of cases, each PV manifests unique intracardiac activation patterns that seem to occur regardless of the site of pace map around the circumference of the vein. While the mechanism for this observation was beyond the scope of this study, we speculate that each PV is connected to the LA by a limited number of inputs/points of continuation of

Table 1. Results of circumferential ostial pace-mapping for all the pulmonary veins

	RSPV (n = 19)	RIPV (n = 8)	LSPV (n = 20)	LIPV (n = 12)
Mean CS – CT time (msec)	37.5 ± 12.4	21.7 ± 24.8	4.9 ± 14.6	–10.3 ± 9.8
Mean Interpolar variation in CS – CT time (msec)	8.3 ± 7.6	11.8 ± 6.6	14.2 ± 7.3	9.6 ± 7.9
Range of Interpolar variation in CS – CT time (msec)	0–30	3–23	5–28	0–30
Pulmonary Veins with significant interpolar variation (≥25 msec)	1/19 (5.3%)	0/8 (0)	2/20 (10.0%)	1/12 (8.3%)

RSPV: right superior pulmonary vein, LSPV: left superior pulmonary vein, RIPV: right inferior pulmonary vein and LIPV: left inferior pulmonary vein. (see text for details).

atrial muscle sleeve into the PV and regardless of the site of pacing around the PV circumference, exit from the vein into the LA would occur at these specific site(s) only, resulting in similar conduction patterns regardless of the circumferential location of the pace map site and hence the insignificant variation in the interpolar CS – CT activation time. Furthermore the observation that complete PV isolation can be achieved by ablating at a limited number of sites at the PV os also supports the deduction of limited connections between the LA and the PVs [12,13]. Similar to our findings, in a recent study, Yamane and colleagues had observed that during pacing, each PV manifests unique surface P wave morphology that did not change when pace-mapping was performed from diametrically opposite locations (superior and inferior) at the os of the left and right superior PVs. While they do not report the intracardiac AP in that study, the lack of any appreciable change in the surface P wave would imply similar intracardiac activation patterns [14].

Lack of influence of the site of pace-mapping around the PV circumference on the intracardiac activation patterns has important implications in developing an accurate template in predicting the vein of origin of spontaneous APCs. However, both the current study and our previous observations suggest an overlap in the intracardiac activation patterns when pace-mapping from same-sided PVs. In the current study, the overlap seemed to be higher for the right-sided as compared with the left-sided PVs. While the reason for this is not clear, one possible explanation could be the presence of special connections between the LSPV and the LA (Ligament of Marshall) allowing distinct activation patterns when pacing around the LSPV circumference which would not result when pacing around the circumference of LIPV and hence lack of overlap between the two. The absence of such a connection(s) for the right-sided PVs can be one reason for the observed overlap [15–17]. The other possibility is that the observed overlap in the circumferential pace-maps of RSPV and RIPV is artificial, and subtle changes in the activation sequence of multipolar catheters in the CS and along the crista may allow for differentiating RS from RIPV circumferential ostial pace-maps. Also, just two intracardiac locations of multipolar catheters may lack sufficient resolution for detecting subtle differences in the intracardiac activation patterns of RSPV and RIPV pace-maps.

Conclusion

Unique intracardiac activation patterns are seen during pace-mapping from individual pulmonic

veins that are not influenced by the circumferential location of the site of pace map. However, overlap in the activation patterns were observed when pace-mapping around the circumference of the ipsilateral veins.

References

1. Haissaguerre M, Jais P, Shah DC, et al. Right and left atrial radiofrequency catheter therapy of paroxysmal atrial fibrillation. *J Cardiovasc Electrophysiol* 1996;7:1132–1144.
2. Haissaguerre M, Jais P, Shah DC, et al. Spontaneous initiation of atrial fibrillation by ectopic beats originating in the pulmonary veins. *N Engl J Med* 1998;339:659–666.
3. Chen SA, Hsieh MH, Tai CT, et al. Initiation of atrial fibrillation by ectopic beats originating from the pulmonary veins. *Circulation* 1999;100:1879–1886.
4. Jais P, Haissaguerre M, Shah DC, et al. A focal source of atrial fibrillation treated by discrete radiofrequency ablation. *Circulation* 1997;95:572–576.
5. Hsieh MH, Chen SA, Tsai C, et al. Double multielectrode mapping catheters facilitate radiofrequency catheter ablation of focal atrial fibrillation originating from the pulmonary veins. *J Cardiovasc Electrophysiol* 1999;10:136–144.
6. Ashar MS, Pennington J, Callans DJ, et al. Localization of arrhythmogenic triggers of atrial fibrillation. *J Cardiovasc Electrophysiol* 2000;11:1300–1305.
7. Lee SH, Tai CT, Lin WS, et al. Predicting the arrhythmogenic foci of atrial fibrillation before atrial transeptal procedure: Implication for catheter ablation. *J Cardiovasc Electrophysiol* 2000;11:750–757.
8. Movsowitz C, Schwartzman D, Callans DJ, et al. Idiopathic right ventricular tachycardia: Narrowing the anatomic location for successful ablation. *Am Heart J* 1996;131:930–936.
9. Tracy CM, Swartz JF, Fletcher RD, et al. Radiofrequency catheter ablation of ectopic atrial tachycardia using paced activation sequence mapping. *J Am Coll Cardiol* 1993;21:910–917.
10. Schweikert RA, Lugones AP, Kanagaratnam L, et al. A simple method of mapping atrial premature depolarizations triggering atrial fibrillation. *PACE* 2001;24:22–27.
11. Hocini M, Haissaguerre M, Shah DC, et al. Multiple sources initiating atrial fibrillation from a single pulmonary vein identified by circumferential catheter. *PACE* 2000;23:1828–1831.
12. Haissaguerre M, Jais P, Shah DC, et al. Electrophysiological end point for catheter ablation of atrial fibrillation initiated from multiple pulmonary venous foci. *Circulation* 2000;101:1409–1417.
13. Edward Gerstenfeld, David Callans, Sanjay Dixit, et al. Utility of Exit Block for Identifying Electrical Isolation of the Pulmonary Veins (Abstract). *Circulation* 2001;104(suppl II):II-543.
14. Yamane T, Shah DC, Peng JT, et al. Morphological characteristics of P waves during selective pulmonary vein pacing. *J Am Coll Cardiol* 2001;38:1505–1510.
15. Ho SY, Sanchez-Quintana D, Cabrera JA, et al. Anatomy of the left atrium: Implications for radiofrequency ablation of atrial fibrillation. *J Cardiovasc Electrophysiol* 1999;10:1525–1533.

16. Chauvin M, Shah DC, Haissaguerre M, et al. The anatomic basis of connections between the coronary sinus musculature and the left atrium in humans. *Circulation* 2000;101:647–652.
17. Hwang C, Karagueuzian HS, Chen PS. Idiopathic paroxysmal atrial fibrillation induced by a focal discharge mechanism in the left superior pulmonary vein: Possible roles of the ligament of Marshall. *J Cardiovasc Electrophysiol* 1999;10:636–648.