

A Comparison of Left Atrial Size by Two-Dimensional Transthoracic Echocardiography and Magnetic Endocardial Catheter Mapping

VICKAS V. PATEL, JIAN-FANG REN, and FRANCIS E. MARCHLINSKI

From the Section of Electrophysiology, Cardiovascular Division, Department of Medicine, Hospital of the University of Pennsylvania, Philadelphia, Pennsylvania

PATEL, V.V., ET AL.: A Comparison of Left Atrial Size by Two-Dimensional Transthoracic Echocardiography and Magnetic Endocardial Catheter Mapping. *This study sought to validate the accuracy of magnetic electroanatomic mapping (MEAM) for determining cardiac chamber size in a clinically relevant situation. The authors chose to compare LA size measured by MEAM to that assessed by two-dimensional guided M-mode echocardiography. The study included 37 patients with drug refractory paroxysmal atrial fibrillation who underwent two-dimensional echocardiography and a detailed MEAM of the LA. The entire LA was mapped with a mean of 132 ± 50 points with attention to identifying the mitral annulus and posterior wall of the LA. The MEAM measurement of LA size was taken as the distance from the anterior wall of the LA to the posterior wall in a plane parallel to the mitral valve annulus at atrial end-diastole. LA dimension determined by M-mode echocardiography was assessed in a plane parallel to the mitral valve annulus in the parasternal long-axis view during atrial end-diastole. LA size assessed by M-mode echocardiography was 41.2 ± 5.0 versus 40.9 ± 4.5 mm as assessed by MEAM, with good correlation ($r = 0.87$, $P < 0.001$). Only three patients had a difference in LA size that was > 0.3 cm between the two measurement techniques. Thus, it appears that LA anteroposterior dimension as determined by electroanatomic mapping is similar to that determined by two-dimensional guided M-mode echocardiography. MEAM appears to be an accurate method by which LA size can be assessed in patients with drug refractory atrial fibrillation undergoing left atrial ablation procedures. (PACE 2002; 25:95-97)*

electroanatomic mapping, echocardiography, left atrial size

Introduction

The present standard, and most commonly used technique in clinical practice, for determining left atrial (LA) size is two-dimensional guided M-mode echocardiography.¹ Magnetic electroanatomic mapping (MEAM) creates an anatomic shell of the endocardial surface of the chamber being mapped and may be another technique for accurately assessing chamber size. Current generated by a location sensor at the tip of the mapping catheter allows for the identification of the catheter tip at the intersection of three low strength magnetic fields.² Electrophysiological information recorded from the catheter tip can be directly coupled to the endocardial anatomic location. When the roving catheter is moved in three-dimensional space, its location relative to a reference placed on the patient's back is continuously monitored with a resolution of < 1 mm.³ Given this high spatial resolution, it would appear reasonable to assume that chamber size determined using this mapping system should also be precise. An additional accurate

and reliable method for determining LA size could prove valuable in those patients with atrial fibrillation (AF) undergoing LA mapping and ablation. The creation of the three-dimensional shell of the LA using this system has been reported to facilitate ablation of focal triggers for paroxysmal AF.⁴ The purpose of this study was to determine the accuracy of LA anteroposterior linear dimension determined by MEAM compared to the clinical standard of two-dimensional guided M-mode echocardiography in patients with drug refractory AF.

Patients and Methods

Patients

The study group included 37 (31 men, 6 women) patients with symptomatic drug refractory AF who were referred for focal AF ablation. The mean age was 49 ± 14 years (range 21-75 years). All of the patients had a history of paroxysmal AF. The history of symptomatic AF ranged from 3 to 360 months with a mean duration of 59 months. The median number of failed antiarrhythmic drugs was four with a range of one to seven. The left ventricular ejection fraction was normal in 35 patients and mildly depressed (range 0.40-0.50) in two patients. Echocardiograms were obtained for all patients during the same hospitalization as when the mapping/ablation procedure was performed. The time between the two procedures ranged from 0 to 5 days with a median of 2 days.

Address for reprints: Francis E. Marchlinski, M.D., Hospital of the University of Pennsylvania, 3400 Spruce St., Ninth Floor Founders Pavilion, Philadelphia, PA 19104. Fax: (215) 662-2879; e-mail: marchlin@mail.med.upenn.edu

Received June 12, 2001; accepted July 12, 2001

Methods

MEAM was performed using a 7 Fr deflectable catheter (CARTO Webster Biosense Inc., Diamond Bar, CA, USA). The catheter was placed in the LA via the standard Brockenbrough transeptal technique.⁵ All aspects of the LA were mapped in detail during sinus rhythm at atrial diastole under the guidance of fluoroscopy and electroanatomic mapping. A mean of 132 ± 50 points were sampled (range 67–189 points) with care taken to define the location of the mitral valve annulus and each of the pulmonary veins in every patient. The LA size was assessed by clipping the three-dimensional endocardial shell created from the detailed LA map in the anteroposterior plane and digitally measuring the distance from the anterior to the posterior wall in a plane near the mitral valve annulus (Fig. 1). LA size was assessed by two-dimensional M-mode echocardiography by taking the anteroposterior linear dimension of the chamber in the parasternal long-axis view at atrial end-diastole during sinus rhythm (Fig. 1). All LA size measurements by MEAM were made inde-

pendent of any prior knowledge of the LA size as determined by the echocardiogram. The correlation coefficient comparing echocardiographic versus MEAM results were computed using a linear regression model with a P value < 0.05 indicating a significant difference.

Results

LA size as assessed by two-dimensional guided M-mode echocardiography was 41.2 ± 5.0 vs 40.9 ± 4.5 mm as assessed by MEAM (Figs. 1 and 2). The measurements obtained by the two different techniques were well correlated with a high degree of significance $r = 0.87$, $P < 0.001$. Of the 37 patients, only 3 patients had a difference in LA size that was > 0.3 cm between the two measurement techniques (Fig. 2).

Discussion

The present study shows that the determination of LA size by MEAM is similar to that determined by transthoracic two-dimensional guided M-mode echocardiography. The correlation observed

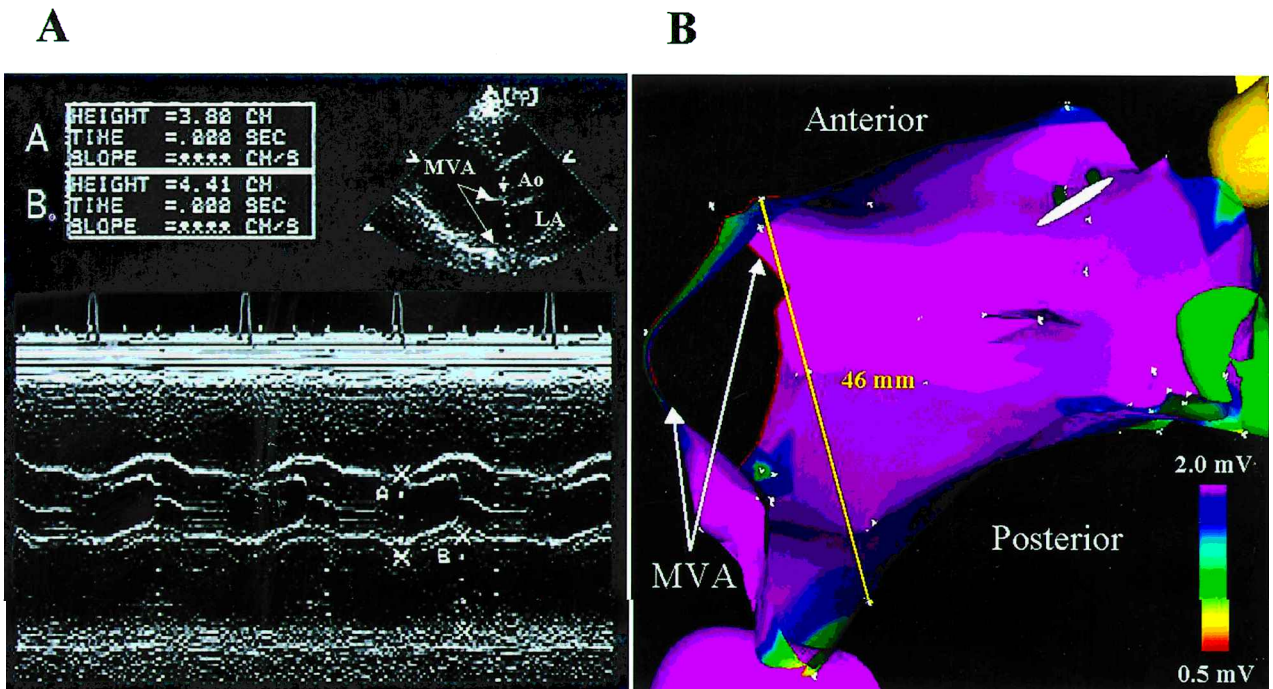


Figure 1. (A) Freeze-frame image of the transthoracic echocardiogram from a representative patient showing the two-dimensional guided M-mode assessment of LA size. Insert at the upper right of the panel shows the two-dimensional image in the parasternal long-axis view with the M-mode cursor across the aortic root and LA. Note that the cursor is placed close to the mitral valve annulus in this view. The main panel shows the resulting M-mode image with calipers (labeled B) at the edge of the anterior (top) and posterior (bottom) walls of the LA. (B) Electroanatomic map of the LA from the same patient oriented in a modified craniocaudal view. The map is clipped in the transverse plane with the mitral valve annulus at the left of the image. The solid line spans the anterior and posterior walls of the LA with the linear distance displayed as measured by the digital calipers. Ao = aorta; LA = left atrium; MVA = mitral valve annulus.

for LA size determination between the two measurement techniques in this study ($r = 0.87$) is comparable to that reported in the initial studies looking to validate LA size determination by M-mode echocardiography in comparison to cineangiography ($r = 0.88$).⁶ Intuitively, LA size as assessed by MEAM should be very accurate. This technique has been documented to have a precision of ~ 1 mm for locating points in space,³ thus exact chamber dimensions should be achievable. The authors are aware of the fact that it would have probably been more accurate to compare LA volume using the two measurement techniques.⁷ However, they chose to compare anteroposterior LA dimension because M-mode echocardiography remains the most widely used echocardiographic technique in clinical practice for assessing LA size. To their knowledge, this is the first comparative study done to establish the spatial accuracy of MEAM for defining chamber size in a clinically relevant situation.

Although the LA size determination by the two techniques is close, it is interesting to speculate why differences in size (> 0.3 cm) were identified in about 8% of the patients. The most likely source of error introduction in this study is from deviations in the angle across the LA at which the dimensions of the chamber were measured between the two techniques. The angle and location at which the LA size was measured with the electroanatomic map was approximated to best match those made with the M-mode echocardiogram. Obviously, such approximations will introduce error, but the fact that none of the measurements deviated by more than 0.4 cm ($< 10\%$ of the mean LA dimension) from each other argues that the approximations in this study were reasonably accurate. In addition, only a small number of the measurements (3/37) deviated from each other by 0.4 cm and this also supports the argument that the approximations made in measuring the LA size were reasonable. In addition, mapping with a catheter may result in some distention due to catheter tension and this could also introduce error. Other differences may be related to the impact of recent paroxysms of

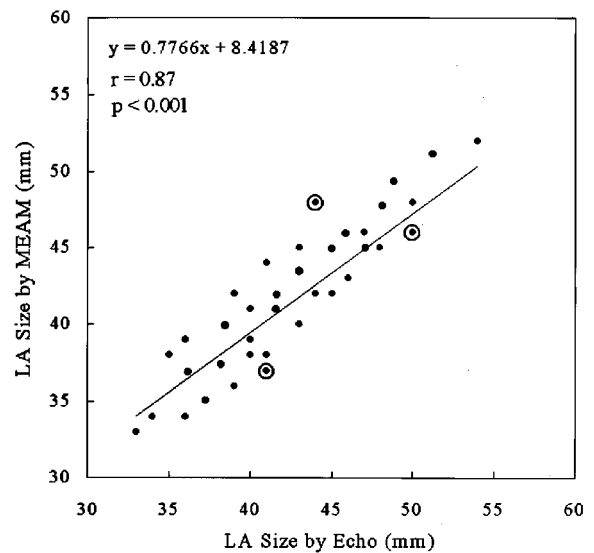


Figure 2. The relationship between LA size as assessed by two-dimensional guided M-mode echocardiography and MEAM for all 37 patients. The straight line is the best fit to the data points as computed by a linear regression model. The correlation of LA size as assessed by the two different measurement methods is good and highly significant ($r = 0.87$, $P < 0.001$). Three of the 37 patients had a difference in LA size of 0.4 cm as assessed by the two measurement techniques (circled points). LA = left atrium; MEAM = magnetic electroanatomic mapping.

AF and/or the difference in volume conditions between the time of the two measurements.

Given the high correlation of atrial size with the incidence of AF,⁸ the ability to assess LA size at the time of ablation may be useful to help plan additional mapping or ablation strategies in those patients with an enlarged LA. In addition, for those patients who require repeat procedures, LA size may be reliably tracked with MEAM during subsequent procedures. This is important because increasing LA dimension, as measured by two-dimensional guided M-mode echocardiography, has been shown to be associated with an increased risk of recurrence of AF.⁹

References

1. Sahn DJ, DeMaria A, Kisslo J, et al. Recommendations regarding quantitation in M-mode echocardiography: Results of a survey of echocardiographic measurements. *Circulation* 1978; 58: 1072-1083.
2. Gepstein L, Hayam G, Ben-Hain SA. A novel method for nonfluoroscopic catheter-based electroanatomic mapping of the heart. *Circulation* 1997; 95:1611-1622.
3. Gepstein L, Evans SJ. Electroanatomical mapping of the heart: Basic concepts and implications for the treatment of cardiac arrhythmias. *PACE* 1998; 21:1268-1278.
4. Pappone C, Oreto G, Lamberti F, et al. Catheter ablation of paroxysmal atrial fibrillation using a 3D mapping system. *Circulation* 1997; 96:2715-2721.
5. Brockenbrough EC, Braunwald E. A new technique for left ventricular angiocardiography and transseptal left heart catheterization. *Am J Cardiol* 1960; 6:1062-1068.
6. Ten Cate FJ, Kloster FE, van Dorp WG, et al. Dimensions and volumes of left atrium and ventricle determined by single beam echocardiography. *Br Heart J* 1974; 36:737-746.
7. Lester SJ, Ryan EW, Schiller NB, et al. Best method in clinical practice and in research studies to determine left atrial size. *Am J Cardiol* 1999; 84:829-832.
8. Henry WL, Morganroth J, Perlman AS, et al. Relation between echocardiographically determined left atrial size and atrial fibrillation. *Circulation* 1976; 53:273-279.
9. Ommen SR, Tsang TSM, Ammass NM, et al. Usefulness of serial echocardiographic parameters for predicting the subsequent occurrence of atrial fibrillation. *Am J Cardiol* 2001; 87:1298-1301.