

Right Bundle-Branch Block Ventricular Tachycardias Septal Versus Lateral Ventricular Origin Based on Activation Time to the Right Ventricular Apex

Vickas V. Patel, MD, PhD; Robert W. Rho, MD; Edward P. Gerstenfeld, MD; Henry H. Hsia, MD;
David J. Callans, MD; Francis E. Marchlinski, MD

Background—Identifying the septal versus lateral site of origin of ventricular tachycardia (VT) with a right bundle-branch block (RBBB)–type pattern and an R-S ratio >1 in lead V_1 is difficult with the 12-lead ECG, especially in patients with prior apical infarction.

Methods and Results—We prospectively evaluated 58 patients with VT. Sixteen patients had apical infarcts (group 1), 29 had nonapical infarcts (group 2), and 13 had no heart disease (group 3). QRS complex onset to activation at the right ventricular apex (stim-RVA) was measured during left ventricular (LV) apical septal and lateral pacing, and 47 RBBB-type VTs (QRS-RVA) were localized to the septal or lateral apex by using entrainment techniques. Pacing and VT site of origin were confirmed by electroanatomic mapping. The stim-RVA time was 59 ± 16 ms for septal versus 187 ± 24 ms for lateral sites in group 1, $P < 0.001$; 70 ± 14 ms for septal versus 169 ± 19 ms for lateral sites in group 2, $P < 0.001$; and 42 ± 15 ms for septal versus 86 ± 16 ms for lateral sites in group 3, $P < 0.005$. The QRS-RVA time was 50 ± 13 ms for apical septal VTs versus 178 ± 21 ms for lateral VTs in group 1, $P < 0.001$; 71 ± 17 ms for apical septal versus 157 ± 20 ms for lateral VTs in group 2, $P < 0.001$; and 32 ± 12 ms for septal versus 71 ± 16 ms for lateral VTs in group 3, $P < 0.01$.

Conclusions—The QRS-RVA differs for the VT site of origin from the LV septal versus lateral apex. These data prove useful in rapidly regionalizing the VT site of origin with a V_1 R-S ratio >1 , particularly in instances of an apical infarct, where surface ECG distinctions are less identifiable. (*Circulation*. 2004;110:2582-2587.)

Key Words: tachyarrhythmias ■ bundle-branch block ■ mapping ■ electrophysiology

During catheter mapping of stable unimorphic ventricular tachycardia (VT), ablation at sites demonstrating electrograms recorded in mid to late electrical diastole, with the appropriate response to entrainment techniques, is associated with a high likelihood of successful outcome.^{1,2} For VTs with multiple morphologies, hemodynamic intolerance, or noninducibility, linear lesions targeting the border zone defined by sinus rhythm electroanatomic mapping and placement of lesions guided by pacemapping are also associated with good outcome.^{3,4} In both settings, analysis of the 12-lead ECG during VT serves as a starting point for catheter placement to perform more detailed activation and pacemapping.⁵ A major limitation of using ECG analysis arises when the VT has a right bundle-branch block (RBBB)–type pattern with an R-S ratio >1 in lead V_1 (V_1 -R/S >1) and there is a need to distinguish a septal versus lateral left ventricular (LV) origin. This situation worsens with an apical infarct, wherein an RBBB-type of VT arising from the LV septum has an ECG morphology similar to that originating from the LV lateral

wall.⁵ Despite the presence of an apical scar, the temporal relation between the VT origin and a fixed reference within the heart should remain intact. We hypothesized that the surface QRS onset to a reference electrogram recorded at the right ventricular apical (RVA) septum will be shorter with RBBB-type VTs originating from the LV apical septum compared with those arising from the LV apical lateral wall. In addition, differences in RVA activation between apical septal and lateral-wall RBBB-type VT origin may vary with the endocardial substrate and should be most dramatic in patients with an apical infarct, so characterization of these activation times will provide a useful criterion for rapidly regionalizing RBBB-type VTs in this setting. To test our hypotheses and to confirm the value of the activation time to the RVA, we designed a prospective evaluation using (1) LV apical pacemapping, (2) standard endocardial catheter mapping and entrainment techniques of induced VT sites, and (3) electroanatomic mapping to confirm the LV apical septal or lateral origin in patients both with and without prior myocardial infarction.

Received March 29, 2004; revision received May 28, 2004; accepted June 2, 2004.

From the Section of Cardiac Electrophysiology (V.V.P., R.W.R., E.P.G., H.H.H., D.J.C., F.E.M.) and the Molecular Cardiology Research Center (V.V.P.), University of Pennsylvania Health System, Philadelphia, Pa.

Reprint requests to Francis E. Marchlinski, MD, Hospital of the University of Pennsylvania, 3400 Spruce St, 9th Floor, Founders Pavilion, Philadelphia, PA 19104. E-mail francis.marchlinski@uphs.upenn.edu

© 2004 American Heart Association, Inc.

Circulation is available at <http://www.circulationaha.org>

DOI: 10.1161/01.CIR.0000145542.24347.18

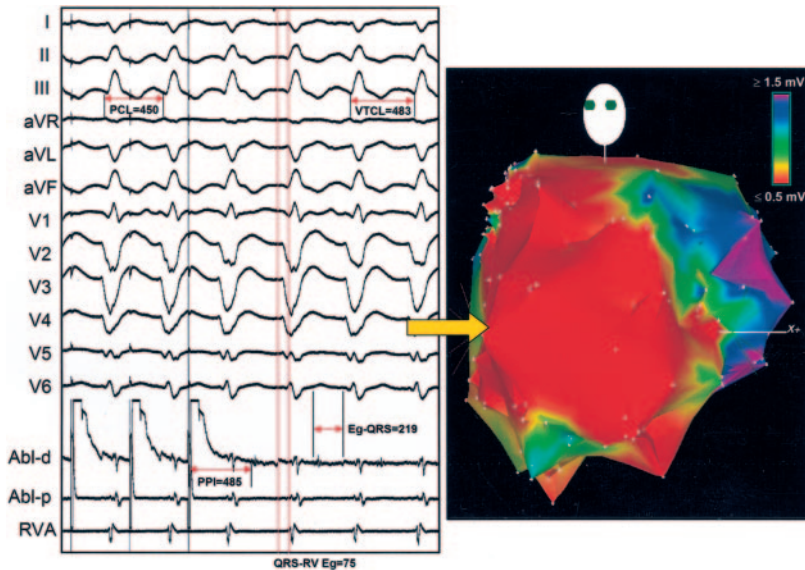


Figure 1. Right bundle right inferior axis VT originating from LV septum in patient with anteroapical infarct. “Site of origin” of this VT could not be accurately determined on basis of 12-lead ECG analysis alone. However, QRS-RVA time of 75 ms suggests that earliest endocardial activation site was near septum. Endocardial entrainment mapping confirmed “site of origin” on LV septum (site mid-2). VT cycle length was 483 ms, and pacing delivered at cycle length (PCL) of 450 ms produced concealed fusion with postpacing interval (PPI) of 485 ms. Electrogram recorded at site of stimulation was middiastolic, with electrogram to QRS time (Eg-QRS) of 219 ms, which places catheter at isthmus of this VT circuit. Electroanatomic voltage map is shown in left anterior oblique projection. Dense scar is denoted by electrogram voltage ≤ 0.5 mV (red) and normal ventricle by electrogram voltage ≥ 1.5 mV (purple). Abl-d denotes distal bipole of mapping catheter; Abl-p, proximal bipole of mapping catheter; RVA, RVA catheter electrogram. All other abbreviations are as defined in text.

Methods

Patient Population

The study population consisted of 45 patients with clinically documented VT and prior myocardial infarction and 13 patients with documented VT and a normal LV who were referred to our institution for electrophysiological study and radiofrequency catheter ablation. All patients had evidence of multiple, unimorphic VT morphologies based on analysis of 12-lead ECGs or stored implantable cardioverter-defibrillator electrograms of arrhythmia events. Patients were divided into 3 groups. Group 1 included 16 patients (mean \pm SD age, 72 ± 7 years; 15 men) with apical infarcts documented by nuclear imaging and left ventriculography (LV ejection fraction, $24 \pm 13\%$). Group 2 included 29 patients (mean age, 70 ± 8 years; 27 men) with infarcts sparing the most apical region confirmed on nuclear imaging (LV ejection fraction, $28 \pm 11\%$); 17 patients had inferoposterior infarcts and 12 had inferolateral infarcts. Group 3 consisted of 13 patients (mean age, 34 ± 9 years; 6 men) with a normal LV according to noninvasive imaging and/or left ventriculography. In group 3, 3 VT morphologies (from 3 individual patients) were mapped to the LV apical septum, which were consistent with idiopathic fascicular VT. In addition, 5 VT morphologies (from 3 separate patients) were mapped to the LV apical lateral wall in the absence of detectable endocardial scar. The remaining patients in group 3 had left-sided outflow tract VT in which the LV endocardium was characterized to rule out scar as a further substrate for ventricular arrhythmias.

Electrophysiological Study

Patients underwent electrophysiological study in the fasting state ≥ 5 half-lives after discontinuing all antiarrhythmic agents except amiodarone. All patients were evaluated after informed, written consent was obtained, and all procedures conformed to the institutional guidelines of the University of Pennsylvania Health System. Routinely, a 6F quadripolar electrode catheter with 5-mm interelectrode spacing (Bard, Inc) was placed at the RVA. A Navistar catheter (Biosense, Inc.), a 7F unidirectional deflectable catheter, was advanced into the LV by a retrograde transaortic approach in 55 patients and by a transeptal approach in 3 patients. Intracardiac electrograms were recorded and displayed simultaneously with 12 surface ECG leads on a multichannel oscilloscope recorder (Prucka Engineering, Inc) at sweep speeds of 100 to 200 mm/s. A programmed digital stimulator (DTU-215, Bloom Associates Ltd) was used to deliver electrical impulses at approximately twice the diastolic threshold (or up to 50 mA), and the filter was set from 30 to 500 Hz. All patients underwent programmed stimulation with up to 3 extrastimuli at 2 ventricular sites. At the time of evaluation,

stable VTs were mapped and localized to their LV site of origin by using entrainment mapping techniques⁶ (Figure 1), with anatomic location of this site confirmed on the electroanatomic map.

Electroanatomic Sinus Rhythm Mapping

The electroanatomic mapping system has been previously described.^{7,8} In brief, the electrogram amplitude recorded from the Navistar catheter at different endocardial locations is shown on a computer display as a voltage map. Detailed LV endocardial mapping was performed during supraventricular rhythm (group 1, 14 patients; group 2, 26 patients; group 3, 13 patients) or paced rhythm in pacemaker-dependent patients. A total of 112 to 334 sites were recorded per ventricle (group 1, 156 to 289 sites; group 2, 148 to 334 sites; group 3, 112 to 234 sites). Electrograms were filtered at 10 to 400 Hz and displayed at 100 mm/s; peak-to-peak amplitude was determined automatically. LV voltage maps confirmed the appropriateness of the grouping, in that group 1 patients all had apical low-voltage areas (< 1.5 mV) consistent with prior infarction, group 2 had nonapical low-voltage areas, and group 3 had normal endocardial voltage (> 1.5 mV) throughout the LV. During LV mapping and ablation, heparin was infused to maintain an activated coagulation time > 250 seconds.

Activation Time From QRS Onset to the RVA Electrogram: Pacing

After creation of a complete LV endocardial electroanatomic map during supraventricular or paced rhythm, the Navistar catheter was positioned at the LV apical septum (Josephson site 2) and the LV apical lateral wall (Josephson site 7) under fluoroscopic and electroanatomic guidance.⁵ Pacing was delivered at cycle lengths of 400 to 600 ms at threshold current output. Measurements were analyzed offline after confirming stable capture for at least 10 consecutive complexes. RBBB-type ECG patterns were produced in all patients with lateral apical pacing and in all but 2 patients with septal apical pacing. The time from the pacing stimulus to the onset of the RVA electrogram was determined by using digital calipers at sweep speeds of 100 to 200 mm/s by 2 independent observers blinded to patient group and pacing site (Figure 2).

Activation Time From QRS Onset to the RVA Electrogram: VT

The site of origin was localized by entrainment mapping for all stable VTs. For inclusion in the analysis, (1) the tachycardia had to have an RBBB-type QRS morphology, (2) the site of origin approximated the exit site of the VT circuit defined as a site recorded in the latter half of electrical diastolic but at least 40 ms before the QRS onset, (3) the

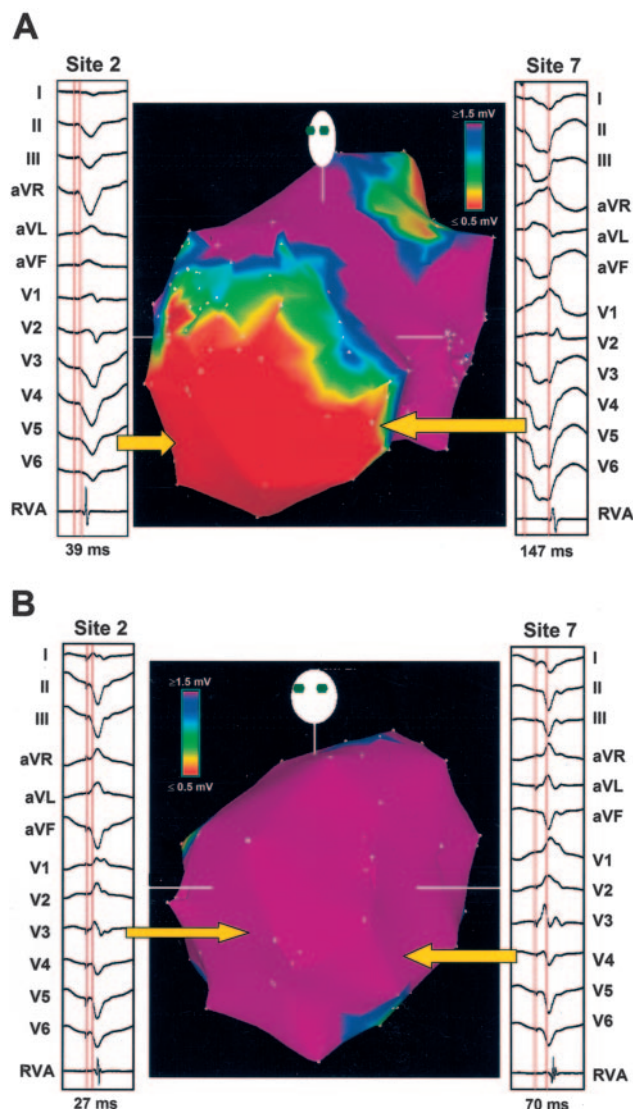


Figure 2. Activation to RVA during LV septal and lateral pacemapping in patients with and without LV endocardial scar. A, Electroanatomic voltage map of LV in left anterior oblique (LAO) projection, showing pacemap electrograms at septum (Josephson site 2) and lateral wall (site 7) from patient with large anteroapical infarct. Note that stim-RVA times are quite distinct between septal and lateral pacing sites. B, Electroanatomic voltage map of LV in LAO projection, showing pacemap electrograms at septum (site 2) and lateral wall (site 7) from patient with normal LV. Pacemap morphology at septal and lateral sites is very different (left axis with narrow QRS complex at septum vs right axis with wider QRS complex at lateral wall), and stim-RVA times are distinct but with less separation than in patient with prior myocardial infarct. In both panels, dense scar is denoted by electrogram voltage ≤ 0.5 mV (red) and normal ventricle by electrogram voltage ≥ 1.5 mV (purple). Red caliper lines depict time from pacing stimulus to onset of RVA electrogram. All other abbreviations are as defined in text.

site demonstrated a 12 of 12 ECG-lead match during pacing at a cycle length 20 to 50 ms shorter than the tachycardia cycle length, and (4) the return cycle after pacing equaled the VT cycle length ± 30 ms.⁶ After the VT site of origin had been defined, the cardiac silhouette and electroanatomic maps were divided into equal apical and basal segments. Tachycardias were included in the analysis when they originated from the apical segment. Tachycardias were defined as lateral or septal on the basis of analysis of catheter tip

location in the left anterior oblique positions on both fluoroscopic and electroanatomic maps. The catheter tip had to be at least 1 cm septal or lateral to the midline position to be included in the analysis. Four tachycardias with RBBB-type morphology that were thought to have originated from the true midapical position (Josephson site 1) were excluded. The time from the earliest QRS complex onset to the RVA electrogram was determined by using digital calipers at sweep speeds of 100 to 200 mm/s by 2 independent observers blinded to patient group and VT site of origin (Figure 3).

Statistical Analysis

All data are expressed as the mean \pm SD unless stated otherwise. Comparison of stim-RVA time with septal versus lateral pacing was made by paired, 2-tailed Student *t* test. Comparison of QRS-RVA activation for apical septal versus apical lateral VT was made with an unpaired, 2-tailed Student *t* test. Determining the influence of the anatomic substrate on LV conduction was done by comparing the stim-RVA times for each group during lateral and septal pacing by ANOVA. A probability value <0.05 was considered significant.

Results

QRS Onset to RVA Electrogram Time With Pacemapping

The stim-RVA activation times are shown in Table 1 for the different patient groups. The stim-RVA activation time when pacing septal sites (Josephson site 2) was significantly different from the stim-RVA time at lateral sites (site 7) for patients in group 1 ($P<0.001$), group 2 ($P<0.001$), and group 3 ($P<0.005$). In patients with a prior apical infarct, the stim-RVA activation was always <100 ms for septal pacing and always >125 ms with lateral pacing. The uniformity of the findings would suggest that these values should prove useful in localizing a VT site of origin from this region in the setting of prior apical infarction.

Importantly, although significant differences in the stim-RVA activation times between septal and lateral pacing were noted in each group, the difference was least marked in the patients without structural heart disease (Table 1). Septal pacing produced a similar stim-RVA activation between the 3 groups (Table 1; $P=NS$). However, lateral pacing produced a much shorter stim-RVA activation time in the patients without structural heart disease ($P<0.01$). Of note, the stim-RVA activation times with lateral pacing in group 1 patients with apical infarct, though modestly longer, were not significantly greater than the stim-RVA activation times in group 2 patients with nonapical infarcts (Table 1).

QRS Onset to RVA Electrogram Time During VT

A total of 165 VT morphologies (induced and spontaneous) were observed during the study (2.8 VTs per patient). Of these, 114 VTs were stable enough for catheter mapping of the LV site of origin by using entrainment mapping techniques (Figure 1). Of the stable VTs, 21 V₁-R/S >1 VTs were mapped to the LV apical septum (group 1, 15 VTs; group 2, 3 VTs; group 3, 3 VTs), and 26 were mapped to the LV lateral apex (group 1, 11 VTs; group 2, 10 VTs; group 3, 5 VTs). The times from the QRS complex onset during VT to the RVA electrogram (QRS-RVA) are shown in Table 2. As with pacing, the QRS-RVA time for septal VTs was significantly different from the QRS-RVA time of the lateral VTs for patients in group 1 ($P<0.001$), group 2 ($P<0.001$), and group 3 ($P<0.01$). Similar to the results of pacemapping, the apical

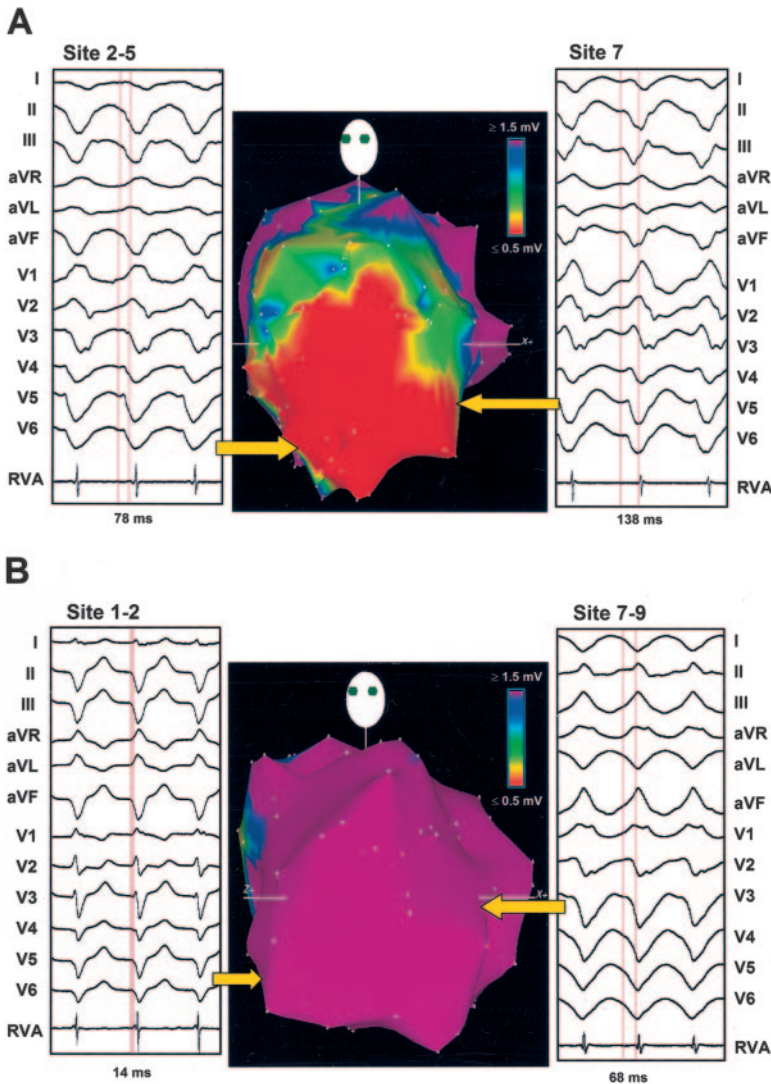


Figure 3. Activation to RVA during VT originating from LV septal and lateral wall in patients with and without LV endocardial scar. A, LV electroanatomic voltage map from patient with apical infarct is shown in left anterior oblique (LAO) projection depicting electrograms of septal VT (Josephson site 2) and lateral VT (sites 7–9). Note that QRS-RVA times are quite distinct, which aid identifying septal vs lateral VT foci. B, Electroanatomic voltage map of LV in LAO projection showing electrograms of septal VT (sites 1–2) and lateral VT (site 7) from patient with normal LV. Morphologies of 2 VT foci at septal and lateral sites are distinct (left axis with narrow QRS complex at septum vs right axis with wider QRS complex at lateral wall), and QRS-RVA times are different but with less separation than in patient with prior myocardial infarct. In both panels, dense scar is depicted by electrogram voltage ≤ 0.5 mV (red) and normal ventricle by electrogram voltage ≥ 1.5 mV (purple). Calipers depict time from onset of earliest surface ECG lead to onset of RVA (red lines). All other abbreviations are as defined in text.

LV septum to RVA activation time was always <100 ms, and the lateral apex to RVA activation time was always >125 ms in the setting of prior apical infarction. The uniformity of the findings and consistency with the pacemapping would suggest that values <100 ms should immediately point to a septal origin and >125 ms to a lateral apical location in a patient with an apical infarction.

Discussion

The surface ECG provides important clues to regionalizing the origin of VT to permit more focused activation and/or pacemapping. Importantly, in the setting of apical infarction,

an RBBB-type of VT morphology with a $V_1\text{-R/S} >1$ is common, but lateral versus septal 12-lead ECG QRS morphologies significantly overlap, with variable early R-wave progression and a similar frontal plane axis.⁵ Thus, in this situation, ECG analysis alone has a more limited value.⁵ The present study describes criteria for rapidly regionalizing a septal versus lateral origin for an apical LV VT with an RBBB-type of QRS morphology by assessing the activation time to a fixed reference endocardial recording at the RVA. This criterion appears to be extremely useful, particularly in the setting of an apical scar, where a marked, nonoverlapping difference in activation time to the RVA is evident with

TABLE 1. Pacemap Stimulus to RVA Electrogram Time

	Site 2 Stim-RVA, ms	Site 7 Stim-RVA, ms
Group 1 (n=16)	59 ± 16* (range, 36–98)	187 ± 24 (range, 136–248)
Group 2 (n=29)	70 ± 14* (range, 32–138)	169 ± 19 (range, 122–203)
Normal LV (n=13)	42 ± 15† (range, 16–50)	86 ± 16 (range, 64–107)

Abbreviations are as defined in text.
* $P < 0.001$, † $P < 0.005$ for all septal stim-RV vs lateral stim-RV times within the same group.

TABLE 2. VT QRS to RVA Electrogram Time

	Septal QRS-RV, ms	Lateral QRS-RV, ms
Group 1	50 ± 13* (range, 27–87, n=15)	178 ± 21 (range, 128–197, n=11)
Group 2	71 ± 17* (range, 31–114, n=3)	157 ± 20 (range, 122–192, n=10)
Normal LV	32 ± 12† (range, 14–49, n=3)	71 ± 16 (range, 55–86, n=5)

Abbreviations are as defined in text.
* $P < 0.001$, † $P < 0.01$ for all septal QRS-RV vs lateral QRS-RV times within the same group.

lateral versus septal LV apical origin. We demonstrated that for an RBBB-type of QRS morphology, created by pacemapping or VT in the setting of an apical infarct (group 1), the QRS-RVA activation time was consistently <100 ms for an apical LV septal origin and >125 ms for a lateral apical origin. The same values for the QRS-RVA activation time will also help to identify septal versus lateral-wall origin in the setting of prior nonapical infarcts.

Although the true value of timing from the QRS onset to an RVA reference lies in its ability to distinguish LV septal from LV lateral-wall RBBB-type VTs during endocardial mapping, one can speculate that this criterion may also be useful for localizing spontaneous VTs recorded by an RVA implantable cardioverter-defibrillator lead. Interrogation of the device may then be able to provide useful information about the origin of clinically significant VTs. However, the lack of a reference surface ECG lead may limit determination of the QRS-RVA time. However, with recent-generation devices, the far-field electrogram may be able to serve as a surrogate for the surface ECG when recorded simultaneously with a true bipolar near-field electrogram at the RVA.

Influence of Disease Substrate on Activation Time to the RVA From the Apical LV Septum and Lateral Wall

We documented no significant influence of anatomic substrate on the time for RVA activation with septal site pacing and VT. However, the variability in activation to the RVA from the LV septum in the setting of prior myocardial infarction was greater, with some delays exceeding 100 ms in patients with nonapical infarction. In contrast, without structural heart disease, the activation time to the RVA was always <50 ms. The mechanism for the occasional dramatic delay to the RVA from the LV septum in the setting of prior infarction is not known but presumably may be related to local conduction delay in the region of the pacing/VT origin and was observed in both group 1 and group 2 patients.^{9,10} Although it is possible that the occasionally long LV septum-to-RVA delays that we observed in patients with prior myocardial infarction, particularly nonapical infarction, were caused by positioning of the RVA reference and/or pacing catheters slightly off the septum, we believe that this is unlikely to be the case in this study, because we took careful measures to ensure that both catheters were on the septum (ie, electroanatomic mapping and fluoroscopy). In addition, as mentioned earlier, the time from the LV septum to the RVA was always quite short in patients without structural heart disease, and it is unlikely that the catheters were misplaced only in those patients with prior myocardial infarction.

In contrast, a lateral-wall origin for pacing or VT produced dramatic differences in activation to the septum, based on the disease substrate (Tables 1 and 2). In the absence of structural heart disease, activation to the RVA typically occurred within 100 ms. Further and occasionally more dramatic delay occurred in patients with prior myocardial infarction, presumably because of further alterations in local conduction. Surprising to us was the observation that during pacing from the lateral apex, significant delays to the RVA were observed, even in the absence of an apical scar. These data suggest

possible complex patterns of activation from lateral-wall sites in the setting of prior myocardial infarction that warrant further investigation.

Comparison With Prior Investigations

One previous investigation has suggested that the timing from the QRS onset to an RVA reference electrode may help differentiate a septal from a lateral site of origin for VT. Almendral et al¹¹ measured the timing from the QRS onset to an RVA reference electrode in 94 episodes of stable, monomorphic VT in 56 patients and showed that with an LBBB-type of VT, the timing was significantly shorter when compared with an RBBB-type of VT. These investigators found that the mean time to the RVA electrogram was 40 ± 34 ms for an LBBB type of VT ($n=63$) versus 95 ± 37 ms for an RBBB type of VT ($P<0.001$) and suggested a lateral origin for most of the RBBB-type VTs. No attempt was made to relate the activation time to the RVA to the site of origin of the RBBB-type VTs or the infarct presence or location. Our study convincingly demonstrates that the timing of activation to the RVA can also be used to distinguish septal versus lateral sites of origin for VTs with an RBBB-type pattern. These data have significant clinical utility when mapping the site of origin of RBBB-type VTs in the setting of a prior apical infarction, wherein dramatic differences in activation are noted, despite the inability to distinguish location on the basis of surface ECG analysis.⁵

Limitations

Several limitations of this study should be considered. First, in some situations, the earliest QRS onset may be difficult to identify. Next, although the surface ECG morphology is more indicative of the location of the VT exit site, the diastolic pathway leading to the exit site may be spatially far removed from this location, so that with large VT circuits, the exit may be located laterally and the diastolic pathway may be closer to the septum, or vice versa. Therefore, using only the timing to the RVA reference may be less useful for guiding placement of successful ablation lines in scar borders with large VT circuits and should be considered in conjunction with other pacing and entrainment mapping criteria. Also, we chose to measure the time from the QRS onset, or pacing stimulus, to the earliest onset of the RV electrogram, which in some cases, may be caused by far-field activation. Although our measurement techniques probably did not significantly affect our findings, this possibility should be kept in mind if these criteria are to be applied during ventricular mapping. In addition, only 3 VTs originating from the LV septum in group 2 qualified for inclusion in this study, and this may limit the significance of our findings in patients with prior nonapical infarcts.

References

1. Morady F, Harvey M, Kalbfleisch SJ, et al. Radiofrequency catheter ablation of VT in patients with coronary artery disease. *Circulation*. 1999;87:363-372.
2. Callans DJ, Zado E, Sarter BH, et al. Efficacy of radiofrequency catheter ablation for ventricular tachycardia in healed myocardial infarction. *J Am Cardiol*. 1998;82:429-432.

3. Marchlinski FE, Callans DJ, Gottlieb CD, et al. Linear ablation lesions for control of unmappable ventricular tachycardia in patients with ischemic and nonischemic cardiomyopathy. *Circulation*. 2000;101:1288–1296.
4. Soejima K, Suzuki M, Maisel WH, et al. Catheter ablation in patients with multiple and unstable ventricular tachycardias after myocardial infarction: short ablation lines guided by reentry circuit isthmuses and sinus rhythm mapping. *Circulation*. 2001;104:664–669.
5. Miller JM, Marchlinski FE, Buxton AE, et al. Relationship of the 12-lead electrocardiogram during VT and endocardial site of origin in patients with coronary artery disease. *Circulation*. 1988;77:759–766.
6. Stevenson WG, Khan H, Sager P, et al. Identification of reentry circuit sites during catheter mapping and radiofrequency ablation of VT late after myocardial infarction. *Circulation*. 1993;88:1647–1670.
7. Ben-Haim SA, Osadchy D, Schuster I, et al. Nonfluoroscopic, in vivo navigation and mapping technology. *Nat Med*. 1996;2:1393–1394.
8. Gepstein L, Hayam G, Ben-Haim SA. A novel method for nonfluoroscopic catheter-based electroanatomic mapping of the heart: in vitro and in vivo accuracy results. *Circulation*. 1997;95:1611–1622.
9. Stevenson WG, Sager PT, Natterson PD, et al. Relation of pace mapping QRS configuration and conduction delay to ventricular tachycardia reentry circuits in human infarct scars. *J Am Coll Cardiol*. 1995;26:481–488.
10. Josephson ME, Waxman HL, Cain ME, et al. Ventricular activation during ventricular endocardial pacing. II: role of pace-mapping to localize the origin of VT. *Am J Cardiol*. 1982;50:11–22.
11. Almendral JM, Grogan EW, Cassidy DM, et al. Timing of the right ventricular apical electrogram during sustained ventricular tachycardia: relationship to surface QRS morphology and potential clinical implications. *Am J Cardiol*. 1984;54:1003–1007.