

# Cardiodermatology: the heart of the connection between the skin and cardiovascular disease

Joel M. Gelfand<sup>1,2</sup>✉, William B. Song<sup>1</sup>, Sinéad M. Langan<sup>3</sup> & Michael S. Garshick<sup>4,5</sup>

## Abstract

The skin and cardiovascular systems are connected in unique and meaningful ways, and many diseases conventionally considered as being limited to one organ system are more closely related than previously believed. Major cardiovascular diseases and phenomena such as infective endocarditis, congestive heart failure, Kawasaki disease and thromboembolism are associated with specific skin findings, and advances in genetics, immunology and clinical epidemiology show that inflammatory dermatological diseases, such as psoriasis, have serious cardiovascular and cardiometabolic consequences. Additionally, commonly used cardiovascular therapies, such as antihypertensive medications, are associated with important cutaneous adverse effects, including photosensitivity, photocarcinogenesis and eczematous skin reactions. Moreover, systemic dermatological therapies, including retinoids, Janus kinase inhibitors and biologics, can alter the risk of cardiovascular and cardiometabolic diseases. In this Review on cardiodermatology, we provide interdisciplinary insights from dermatology and cardiology that will be of practical use to both cardiologists and generalists who manage cardiovascular and cardiometabolic diseases in patients with dermatological findings or histories. We discuss specific skin findings associated with cardiovascular diseases to aid in diagnosis; important cutaneous adverse effects of common cardiovascular therapies, for the purpose of treatment monitoring; and the effect of dermatological diseases and dermatological treatment on cardiovascular risk.

## Sections

Introduction

Skin findings of diseases relevant to cardiology

Skin effects of cardiovascular therapy

Cardiovascular effects of skin disease

Cardiometabolic effects of dermatological treatment

Conclusions

A full list of affiliations appears at the end of the paper. ✉ e-mail: [joel.gelfand@penntestmed.upenn.edu](mailto:joel.gelfand@penntestmed.upenn.edu)

## Key points

- Common and rare skin diseases are of clinical importance to clinical and investigational cardiology.
- The skin functions as a protective barrier and is involved in temperature regulation, immune surveillance, endocrine and exocrine function, and sensation.
- Inflammatory skin diseases such as psoriasis are cardiovascular risk enhancers, warranting more intensive management of traditional cardiovascular risk factors.
- The therapeutic armamentarium for dermatological diseases is rapidly expanding, with many treatments having potential effects on cardiometabolic disease.

## Introduction

The skin functions as a protective barrier and is involved in temperature regulation, immune surveillance, endocrine and exocrine function, and sensation. Thousands of diseases can occur primarily or secondarily in the skin. Many skin diseases are common, affecting more than 10% of the population, whereas others are rare and require substantial expertise for diagnosis and management.

The composition of the skin includes a diverse and abundant immune cell population chiefly comprising dendritic cells and regulatory T cells in addition to macrophages, mast cells and natural killer cells<sup>1</sup>. Normal human skin contains an estimated 20 billion T cells, which is double the number found in the circulation<sup>2</sup>. Over half of these T cells have a tissue-resident memory phenotype<sup>3</sup>. A cutaneous neurosensory-immune interaction is also present, whereby neuropeptides can regulate vasodilatation indirectly via effects on immune cells as well as certain pro-inflammatory cytokines (such as IL-6, IL-17A and tumour necrosis factor (TNF)), which can induce pain<sup>4</sup>. Finally, the cutaneous immune system also interacts with a complex lymphatic and vascular network. Blood flow to the skin accounts for approximately 5% of cardiac output during steady state, which increases up to 60% when extreme thermoregulation is required<sup>5,6</sup>.

This dense vascular system has a crucial role during wound repair, and neovascularization via vascular endothelial growth factor signalling is stimulated across multiple cell types in the skin, such as keratinocytes, macrophages and fibroblasts, in response to injury<sup>7</sup>. Lipids and fatty acids are also present in the skin and have a role not only in barrier permeability<sup>8</sup> but also in inflammation resolution and optimal wound repair through phospholipid metabolites, including bioactive fatty acids and lipid mediators<sup>9</sup>. Therefore, the skin has a crucial role in host defence and, when it becomes dysregulated, the cardiovascular system can be affected in a number of ways. For example, the skin can be a source of infection or chronic inflammation that promotes cardiometabolic disease. Similarly, cardiometabolic diseases can result in abnormal skin function and disease.

In this Review, we summarize key aspects of dermatology that are of relevance to clinical and investigational cardiology, based on our experience and expertise. We discuss specific skin findings associated with cardiovascular diseases to aid in diagnosis; important cutaneous adverse effects of common cardiovascular therapies, for the purpose of treatment monitoring; and the effect of dermatological diseases

such as psoriasis (Fig. 1) and dermatological treatment on cardiovascular risk. Some topics are well established scientifically and clinically, whereas others are emerging or have conflicting data that we highlight in the hope of stimulating further research.

## Skin findings of diseases relevant to cardiology

A variety of adaptive and pathological cardiovascular and cardiometabolic pathways produce skin findings that can be useful for clinical diagnosis. The following key examples, listed in alphabetical order, describe skin signs and symptoms that are associated with cardiovascular or cardiometabolic conditions, together with clinical implications for diagnosis or management. The conditions, with some additional examples, are summarized in Table 1.

### Acute rheumatic fever

Acute rheumatic fever is a delayed complication of pharyngeal and skin infections with *Streptococcus pyogenes* (which can also trigger guttate psoriasis)<sup>10</sup>. The disease is an autoimmune response to the bacteria occurring 1–5 weeks after infection, and affects the heart, joints and central nervous system<sup>11,12</sup>. Pancarditis is the major cardiac manifestation of acute rheumatic fever, occurring in more than 50% of patients, and the most common and specific complication, with long-lasting implications, is valvulitis of the mitral and/or aortic valves<sup>12</sup>. Erythema marginatum (pink, blanching, enlarging and shifting annular and polycyclic lesions on the trunk and limbs) and subcutaneous nodules (less than 2 cm in diameter, firm, painless and mobile) occur in less than 5% of patients. Although uncommon, erythema marginatum is considered to be highly specific for acute rheumatic fever<sup>12,13</sup>.

### Cardiac amyloidosis

Amyloidosis affects many organs and is a cause of restrictive cardiomyopathy. Soft tissue involvement, especially periorbital purpura due to capillary involvement or clotting factor deficiency (10% of patients) and macroglossia due to soft tissue infiltration of amyloid (15% of patients), are highly specific in amyloid light chain amyloidosis, which can also present with muscular pseudohypertrophy, salivary gland swelling and submandibular soft tissue infiltration<sup>14,15</sup>. By contrast, there are no skin-specific findings in patients with transthyretin cardiac amyloidosis.

### Cardiac myxoma and Carney complex

Cardiac myxomas, although rare, are the most common type of primary cardiac neoplasm. Approximately 7% of cardiac myxomas occur as part of Carney complex, a rare genetic syndrome characterized by multiple tumours, lentigines on the skin (particularly on the face, vermilion border of the lips and conjunctiva<sup>16</sup>), increased risk of developing several types of cancer and myxomas in various organ systems, including cardiac myxomas in 20–40% of patients<sup>17</sup>. Approximately 30–55% of patients can also have skin myxomas, which appear as small, sessile, pink papules or pedunculated lesions, typically on the eyelids, ears or nipples<sup>16</sup>. Lentigines and cardiac myxomas are the two major manifestations of Carney complex, so recognition of Carney complex should prompt echocardiographic imaging. Alternatively, the presence of abundant lentigines in someone with a history of cardiac myxoma should prompt evaluation for Carney complex<sup>17</sup>.

### Ehlers–Danlos syndromes

The Ehlers–Danlos syndromes (EDS) are a group of 14 heterogeneous and heritable connective tissue disorders associated with

hyperextensibility and fragility of the skin, abnormal wound healing, hypermobility of joints and potential involvement of many organ systems<sup>18</sup>. Important cardiovascular complications include abnormalities in the arterial vasculature, in particular the formation and rupture of aneurysms, as well as rare dysfunction of the cardiac valves<sup>18</sup>. Among patients in a 35-year registry with vascular EDS type, which is the second most common form of EDS with a known molecular basis after classic EDS, 78% had arterial abnormalities and 46% had arterial aneurysms<sup>18,19</sup>. Aneurysms associated with EDS are found throughout the vasculature, including in large vessels such as the aorta, carotid arteries and intracranial vessels, and as many as 65% of patients who have any aneurysms are found to have multiple aneurysms after further evaluation<sup>20</sup>. Arterial pathology is also found at lower rates in patients with non-vascular EDS<sup>21</sup>. A survey of European expert centres for vascular EDS found that most performed regular arterial screening in asymptomatic patients, usually with a combination of magnetic resonance angiography, CT angiography and/or ultrasonography, and at intervals of 1–5 years based on the individual history and risk of the patients<sup>22</sup>. Other than surgical or endovascular treatment of existing aneurysms, no medical treatments are approved by regulatory agencies for managing aneurysms in patients with EDS, although  $\beta$ -blockers are conventionally used. Celiprolol, a  $\beta_1$ -adrenergic receptor antagonist, partial  $\beta_2$ -adrenergic receptor agonist and weak  $\alpha_2$ -adrenergic receptor

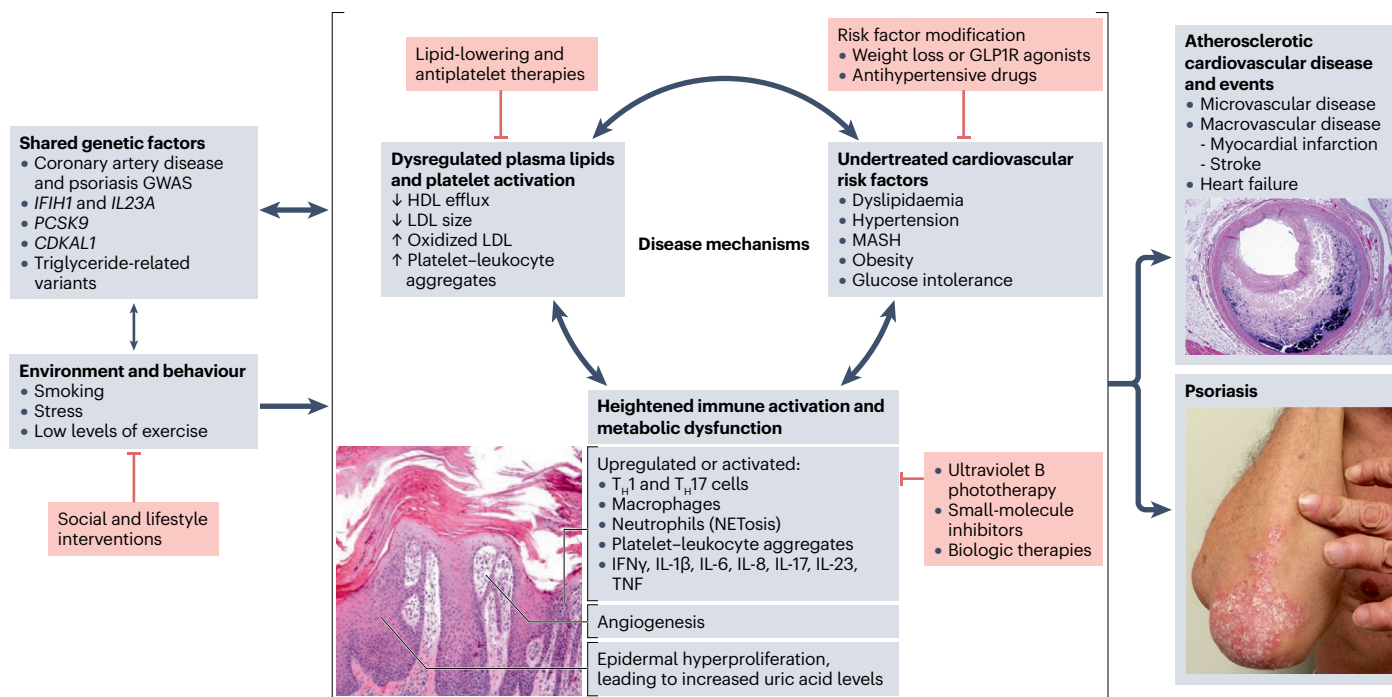
antagonist, might be beneficial in preventing arterial rupture in patients with vascular EDS, according to several limited studies<sup>23–25</sup>. Celiprolol is available in many European countries but is not approved for use in Canada or the USA<sup>26</sup>.

## Infective endocarditis

Infective endocarditis can produce several skin signs caused by micro-emboli. Splinter haemorrhages appear as small red–brown or black longitudinal streaks under the nail plate, and a proximal location on the nail plate has greater diagnostic value, because distal splinter haemorrhages can commonly result from minor trauma to the nail. Janeway lesions appear as painless, irregular, non-blanching, erythematous macules and papules on the palms and soles. Osler nodes are painful, red papules and nodules with a pale centre on the fingertips. Septic emboli from vegetation on the heart valves can cause ischaemia in the distal toes and fingers and can present as reticulated purpura, purple digits or, rarely, tissue necrosis or gangrene. The percentages of patients with endocarditis who have splinter haemorrhages, Janeway lesions or Osler nodes are estimated to be 8%, 4–5% and 2%, respectively<sup>27,28</sup>.

## Kawasaki disease

Kawasaki disease is a multisystem inflammatory disease with an incidence of 25–250 cases per 100,000 children, depending on the



**Fig. 1 | Breaking the cycle of cardiovascular disease in psoriasis.** Psoriasis and atherosclerotic cardiovascular disease have shared genetic, pathogenic, environmental and behavioural risk factors. Studies have identified genetic loci that contribute to both psoriasis and cardiovascular disease, including *IFIH1* and *IL23A*<sup>108</sup>, *PCSK9* (ref. 211), *PSORS2*, *PSORS3* and *PSORS4*, *CDKAL1*, and *APOE* (encoding the apolipoprotein E4 isoform)<sup>212</sup>, and genes encoding proteins related to coronary artery disease<sup>213</sup> and triglycerides<sup>127</sup>. Environmental risk factors such as smoking, stress and low levels of exercise also affect the risk and severity of both psoriasis and cardiovascular disease. Physiological changes characteristic of psoriasis, including dysregulated plasma lipids, heightened immune activation and metabolic dysfunction in the skin, and cardiovascular risk

factors that are frequently undertreated, further contribute to the risk of adverse cardiovascular events<sup>212</sup>. Clinical interventions that modify immune activity and control dyslipidaemia and other cardiovascular risk factors might help to reduce some of the cardiovascular risks in individuals with psoriasis. GLP1R, glucagon-like peptide 1 receptor; GWAS, genome-wide association study; MASH, metabolic dysfunction-associated steatohepatitis; NETosis, neutrophil extracellular trap-dependent cell death;  $T_H1$ , T helper 1 cell;  $T_H17$ , T helper 17 cell; TNF, tumour necrosis factor. Skin histology image courtesy of R. Elenitsas. Atherosclerosis histology image courtesy of PathologyOutlines.com, contributed by R. F. Corliss and J. J. Schulte. Psoriasis image courtesy of J. M. Gelfand.

Table 1 | Selected diseases and conditions with skin findings relevant to cardiology






Conditions and diseases	Clinical images	Skin features	Cardiovascular and cardiometabolic associations
Acanthosis nigricans		Dark, thick and course plaques on the neck and flexural areas and, occasionally, acral areas	Obesity and insulin resistance, with 15–35% of people with acanthosis nigricans and no known history of insulin resistance being diagnosed with type 2 diabetes mellitus on evaluation <sup>174–176</sup> ; rarely, cancer (gastrointestinal adenocarcinoma <sup>177</sup> ) or medication (niacin or insulin <sup>178</sup> ) is responsible for the skin condition
Acute rheumatic fever		Erythema marginatum (pink, blanching, enlarging, shifting annular and polycyclic lesions on trunk and limbs) and subcutaneous nodules (<2 cm in diameter, firm, painless and mobile)	Pancarditis in more than 50% of patients, with the most common complications being valvulitis of the mitral or aortic valves <sup>12</sup>
Calciophylaxis		Painful skin lesions beginning as violaceous mottling and livedo reticularis, progressing to firm purpuric plaques and nodules, and then to black eschars and ulcers	Mortality of 50% at 1 year, primarily due to sepsis and infection <sup>179</sup> ; usually occurs in patients with end-stage renal disease or other kidney dysfunction; 20% of people with calciophylaxis do not have renal disease, termed non-uraemic calciophylaxis <sup>180</sup>
(Cardiac) amyloidosis		Periorbital purpura and macroglossia are highly specific in amyloid light chain amyloidosis <sup>14,15</sup> ; no skin-specific findings in transthyretin cardiac amyloidosis	Amyloidosis is one of the leading causes of restrictive cardiomyopathy, which can lead to low cardiac output, heart failure and death <sup>14</sup>
Cardiac myxoma and Carney complex		Abundant lentigines on the skin as part of Carney complex, particularly on the face, vermillion border of the lips, and conjunctiva; skin myxomas can be present on the eyelids, ears or nipples <sup>16</sup>	7% of cardiac myxomas occur as part of Carney complex, a rare genetic syndrome characterized by multiple tumours, lentigines on the skin, greater risk of developing several types of cancer, and myxomas in various organ systems, including cardiac myxomas in 20–40% of patients <sup>17</sup>



Table 1 (continued) | Selected diseases and conditions with skin findings relevant to cardiology

Conditions and diseases	Clinical images	Skin features	Cardiovascular and cardiometabolic associations
Cutis laxa		Hyperextendable skin that does not or is slow to return to original shape, appearing loose and pendulous	Risk of severe cardiopulmonary complications, including cardiomyopathy, aortic root dilatation, pneumothorax and cardiopulmonary failure <sup>181</sup>
Cyanosis		Blue discoloration of the skin or mucous membranes, best assessed in areas with thin skin and abundant blood supply (cheeks, nose, ears or oral mucosa) <sup>182</sup>	Central cyanosis suggests a cardiopulmonary disease; concurrent vital sign instability suggests septic shock; cyanosis following exposure to an oxidizing agent (dapsone, sulfur-containing drugs, topical benzocaine) suggests methaemoglobinaemia, in which oxygen saturation measured on pulse oximetry can be falsely normal due to the unique light absorption patterns of methaemoglobin <sup>183</sup> ; vasospasm in response to cold exposure can cause peripheral cyanosis
Diagonal earlobe crease		Diagonal wrinkle across the earlobe from the tragus to the edge of the earlobe	Observational studies report an association with coronary artery disease and worse survival after myocardial infarction; a review of 13 studies found that its diagnostic accuracy was insufficient for routine use in screening <sup>184</sup>
Ehlers–Danlos syndromes		Disorders generally share hyperextensibility and fragility of the skin, abnormal wound healing and hypermobility of joints	Arterial aneurysms and rupture are common in vascular Ehlers–Danlos syndrome and occur at lower rates in other types of the syndrome; cardiac valve dysfunction is rare <sup>18,19</sup>

Table 1 (continued) | Selected diseases and conditions with skin findings relevant to cardiology




Conditions and diseases	Clinical images	Skin features	Cardiovascular and cardiometabolic associations
Erythroderma		Clinical syndrome of widespread erythema of the skin	Associated with skin barrier defects and can cause widespread dilatation of blood vessels, fluid and heat loss, infection and high-output heart failure if untreated <sup>185</sup>
Infective endocarditis		Splinter haemorrhages (small red–brown or black longitudinal streaks under the nail plate), Janeway lesions (painless, irregular, non-blanching, erythematous macules and papules on the palms and soles) and Osler nodes (painful, red papules and nodules with a pale centre on the fingertips); ischaemia of distal digits can present as reticulated purpura, purple digits, tissue necrosis or gangrene	Embolic events, congestive heart failure, cardiac conduction abnormalities, stroke, cardiogenic and septic shock, and death <sup>28</sup>
Kawasaki disease		Bilateral, non-exudative conjunctival injection; oral mucosal changes, including red, dry, cracked lips, pharyngeal erythema or strawberry tongue; erythema of palms and soles or swelling of the hands and feet during the acute phase, or periungual desquamation of the fingers and toes during the subacute phase; rash that is erythematous, morbilliform, scarlatiniform or targetoid	One of the most common causes of acquired heart disease in children in Europe, Japan and North America due to coronary artery aneurysms, thrombosis and stenosis <sup>29,30</sup> ; coronary artery aneurysms can develop in 25% of untreated patients, although timely initiation of treatment reduces this complication to 4% <sup>29</sup>
Lower extremity ulcers		Ulcers with variable appearance and surrounding skin findings based on cause (pictured is a venous leg ulcer in the gaiter area, with typical bluish–brown discoloration)	Commonly associated with peripheral artery disease, chronic venous disease or neuropathy, with risk of infection

Table 1 (continued) | Selected diseases and conditions with skin findings relevant to cardiology

Conditions and diseases	Clinical images	Skin features	Cardiovascular and cardiometabolic associations
Noonan syndrome with multiple lentigines		Multiple lentigines and distinct facial features	Substantial risk of hypertrophic cardiomyopathy and possible abnormalities with left ventricular outflow tract obstruction, pulmonary valve stenosis, valvular abnormalities or conduction abnormalities <sup>39,41</sup>
Pseudoxanthoma elasticum		Yellow, flat-topped, and discrete and confluent papules in the creases of the neck, perineum, axillae, umbilicus and flexural folds; calcification of the skin and infiltrative mucosal lesions can also occur	Mineralization of arterial vessels can lead to gastrointestinal bleeding, intermittent claudication, hypertension and, rarely, early myocardial infarction <sup>181,186</sup>
Sarcoidosis		Macules, papules and plaques that are red, violet or brown; subcutaneous and palpable nodules (Darier–Roussy sarcoidosis); and lupus pernio, a type of sarcoidosis with characteristic violet, indurated plaques on the nose and central face; also non-specific skin manifestations such as erythema nodosum	Cardiac involvement in sarcoidosis is an important source of morbidity and mortality due to the risk of heart failure and arrhythmias <sup>187</sup> ; some data suggest that cutaneous involvement with sarcoidosis is associated with a higher prevalence of cardiac involvement in Black patients, who also have a higher risk of more severe systemic disease <sup>188,189</sup>
Takayasu arteritis		Skin lesions resembling erythema nodosum or pyoderma gangrenosum and Raynaud phenomenon	Commonly presents with limb claudication that can progress to limb pulselessness, dizziness and hypertension and, eventually, stroke, acute coronary syndrome or bowel infarction
Xanthomas		Variable presentation of lipid deposits on the skin	Eruptive xanthomas, tuberous xanthomas, tendinous or tendon xanthomas, and palmar xanthomas can be associated with lipid disorders and the risk of cardiovascular disease; xanthelasma are typically not specifically associated with underlying lipid disorders, and plane xanthomas are associated with cholestatic disorders, paraproteinaemias and lymphoproliferative diseases

Image of diagonal earlobe crease reproduced with permission from ref. 190. Images of infective endocarditis courtesy of M. Rosenbach. Image of pseudoxanthoma elasticum courtesy of M. Lebowhl. Images of xanthomas courtesy of C. Samlaska. All other images reproduced with permission from VisualDx.

country<sup>29</sup>. Kawasaki disease is one of the most common causes of acquired heart disease in children in North America, Europe and Japan due to coronary artery aneurysms, thrombosis and stenosis<sup>29,30</sup>. The cause of Kawasaki disease is unknown but is suspected to be due to an unknown viral pathogen leading to activation of IL-1 signalling and systemic inflammation<sup>30</sup>. Diagnostic criteria based on US guidelines include an intermittent high fever for at least 5 days and having at least four out of five clinical features: bilateral, non-exudative conjunctival infection (89–92% of patients<sup>31,32</sup>); oral mucosal changes, including red, dry, cracked lips, pharyngeal erythema or strawberry tongue (88–97%); erythema of the palms and soles or swelling of the hands and feet during the acute phase, or periungual desquamation of the fingers and toes during the subacute phase (76–87%); a rash that is erythematous, morbilliform, scarlatiniform or targetoid (84–96%); or cervical lymphadenopathy >1.5 cm in diameter (63–79%)<sup>29,33,34</sup>. The 2020 Japanese guidelines consider fever as a major clinical feature rather than a necessary feature, and these guidelines also omit requirements for the duration of fever due to the high rate of treatment initiation before 5 days of fever<sup>35</sup>.

Coronary artery aneurysms can develop in 25% of untreated patients with Kawasaki disease, although timely initiation of treatment reduces this complication to 4%<sup>29</sup>. The US guidelines recommend echocardiography to evaluate coronary and other cardiac abnormalities as soon as Kawasaki disease is suspected, although treatment should not be delayed for this evaluation, and a normal echocardiogram in the first week of illness is common and does not rule out Kawasaki disease<sup>29</sup>. Patients without complications should receive follow-up echocardiography 1–2 weeks and 4–6 weeks after treatment, although patients with expanding large aneurysms can be evaluated more frequently. Standard treatment includes intravenous immunoglobulin therapy and aspirin to prevent coronary aneurysms. A review of eight randomized controlled trials found that the adjunctive use of corticosteroids had moderate-certainty evidence for reducing coronary artery abnormalities, inflammatory markers and duration of hospital stay, without severe adverse events, when used as first-line treatment alongside intravenous immunoglobulin therapy during the acute phase of disease<sup>29,36</sup>. Another review of four randomized controlled trials found that the use of infliximab as a second-line therapy had moderate-certainty evidence for possibly reducing the incidence of treatment resistance in refractory Kawasaki disease<sup>29,37</sup>. The US guidelines recommend that ciclosporin, plasma exchange and cytotoxic agents such as cyclophosphamide be considered only in patients who are refractory to multiple courses of treatment<sup>29</sup>. Long-term thromboprophylaxis with low-dose aspirin, antiplatelet agents,  $\beta$ -blockers or statins can be considered based on the size and progression of residual coronary aneurysms<sup>29,35</sup>.

## Lower extremity ulcers

Lower extremity ulcers are important skin findings that should trigger an evaluation of the vascular health of a patient. Several common causes are possible. Peripheral artery disease can present with painful ulcers with irregular borders and a pale base due to arterial occlusion and ischaemia, most often on the tips of the toes or heel of the foot. These ulcers are associated with surrounding hair loss, coldness, cyanosis, and thickened and malformed toenails and, in severe cases, the skin can become atrophic, dry and shiny, and gangrene can develop. Chronic venous disease presents with lower extremity ulcers below the knee, typically in the 'gaiter' area proximal to the medial malleolus, and is associated with skin fibrosis, varicose veins, oedema, leg pain, stasis

dermatitis and lipodermatosclerosis. Neuropathic ulcers develop with a combination of neuropathy (most commonly secondary to diabetes mellitus) and pressure points, making the heel and metatarsal heads of the foot common locations for presentation. Lower extremity ulcers are evaluated using a combination of ankle–brachial index, pulse volume recordings and CT-guided imaging approaches. In the absence of arterial disease, venous insufficiency can be diagnosed clinically and occasionally using venous reflux studies. If neuropathy is present, the cause should be determined. The presence of purulence, wet gangrene, or surrounding tissue erythema and swelling should prompt evaluation for infection<sup>38</sup>.

## Noonan syndrome with multiple lentigines

Noonan syndrome with multiple lentigines (NSML), previously named LEOPARD syndrome, is part of the RASopathy group of developmental, multisystem disorders that have mutations in the RAS pathway and are associated with a substantial risk of hypertrophic cardiomyopathy<sup>39</sup>. NSML most commonly presents with multiple lentigines on the skin (86% of patients), particular facial features such as a broad forehead and wideset, droopy eyes (90%), structural cardiac abnormalities (71%) and sensorineural deafness (25%)<sup>40</sup>. Hypertrophic cardiomyopathy and concomitant left ventricular outflow tract obstruction comprise the majority of cardiac abnormalities in NSML, and patients can also have pulmonary valve stenosis, valvular abnormalities or conduction abnormalities<sup>41</sup>. Medical therapy should be used in patients with NSML who are found to have hypertrophic cardiomyopathy to reduce the risk of heart failure<sup>39</sup>.

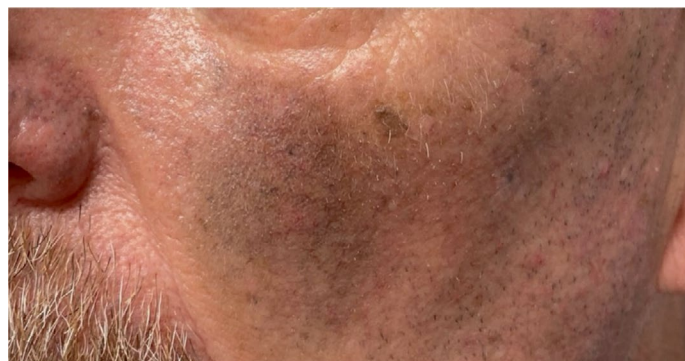## Takayasu arteritis

Takayasu arteritis is a rare, large-vessel vasculitis affecting the aorta and its major branches. The condition commonly presents with limb claudication that can progress to pulselessness in the limb, dizziness and hypertension and, eventually, stroke, acute coronary syndrome or bowel infarction. In several case series, 26–32% of patients with Takayasu arteritis developed skin lesions, including lesions resembling erythema nodosum or pyoderma gangrenosum and Raynaud phenomenon<sup>42,43</sup>. Diagnosis is made based on a high index of clinical suspicion in patients who can present with asymmetric pulses (a >10 mmHg difference in blood pressure between the arms) and limb claudication. Diagnosis is frequently made with a combination of CT and MRI. Characteristic coronary findings in patients with Takayasu arteritis are usually of the coronary ostium. If a lesion is clinically significant enough to require a coronary artery bypass graft, the left internal mammary artery should be assessed before bypass surgery, to exclude mammary artery involvement<sup>44</sup>. Skin biopsy samples often show vasculitis, differentiating the lesion from typical erythema nodosum<sup>45</sup>.

## Xanthomas

Xanthomas are localized lipid deposits on the skin that are themselves benign, but which can be indicative of a primary or secondary disorder of lipid metabolism<sup>46</sup>. Xanthelasma are the most common form of xanthoma (with all other types being rare) and are yellow macules, papules or plaques that usually appear on the upper eyelids near to the inner canthus and are not specifically associated with underlying lipid disorders<sup>47</sup>. Eruptive xanthomas appear as red–yellow papules on the extensor surfaces of extremities and the buttocks, often forming a confluent rash, and are associated with severe hypertriglyceridaemia<sup>46</sup>. Tuberous xanthomas appear as pink, red or yellow nodules in areas of





**Fig. 2 | Amiodarone-induced pigmentation on the face.** Pigmentation on the cheek, sparing the nasolabial folds, is seen in a patient taking the antiarrhythmic drug amiodarone. Image courtesy of H. Lim.

skin that frequently experience pressure and can be associated with familial hypercholesterolaemia, which presents with plasma LDL cholesterol levels of 350–500 mg/dl or higher<sup>46,48–50</sup>. Tendinous (or tendon) xanthomas appear as firm, subcutaneous nodules in fascia, ligaments and extensor tendons and can be found in as many as 30% of people with any type of familial hypercholesterolaemia<sup>51</sup>. One meta-analysis showed that, among people with familial hypercholesterolaemia, the presence of tendinous xanthomas was associated with a 3.2-fold higher risk of developing cardiovascular disease than those without tendinous xanthomas<sup>52</sup>. Palmar xanthomas appear as yellow nodules or plaques affecting the flexural surfaces of fingers and the creases of palms and soles and are associated with familial dysbetalipoproteinaemia. Plane xanthomas, which appear as yellow to orange lesions on the axillae, neck, shoulders or buttocks, are associated with cholestatic disorders, paraproteinaemias and lymphoproliferative diseases. Clinicians who identify lipid-related xanthomas should screen patients for underlying dyslipidaemia. Young patients with xanthomas or patients with suspected familial dyslipidaemias should receive lipid screening (which generally can start as young as 2 years of age), counselling and lipid screening of all first-degree relatives<sup>47</sup>.

## Skin effects of cardiovascular therapy

### Photosensitivity and photocarcinogenesis

Photosensitivity skin reactions are caused or exacerbated by sunlight exposure. Reactions can be phototoxic or photoallergic, with phototoxic reactions being most relevant to cardiology. Phototoxicity is caused by direct cellular damage from photoactivated compounds via a non-immunological pathway (often by generation of reactive oxygen species)<sup>53</sup>.

Thiazide diuretics cause photosensitivity through exposure to ultraviolet A, resulting in lipid peroxidation and DNA damage. Hydrochlorothiazide, which is most commonly associated with thiazide-related photosensitivity, is estimated to cause phototoxicity in 1 in 100 to 1 in 10,000 patients<sup>53</sup>. Even in the absence of clinical signs or symptoms of phototoxicity, increasing evidence supports associations between hydrochlorothiazide use and an increased risk of cutaneous squamous cell carcinoma, with the risk of squamous cell carcinoma increasing with higher cumulative doses of hydrochlorothiazide<sup>54</sup>. Amiodarone causes phototoxicity in 25–75% of patients and can cause blue–grey discoloration of sun-exposed skin in 4–9% of patients<sup>55</sup> (Fig. 2), possibly due to deposition of the drug and its

metabolites in dermal tissue<sup>56</sup>. The development of skin discoloration is related to cumulative doses of  $\geq 40$  g after at least several months of treatment<sup>57</sup>, although discoloration has also been reported at lower doses<sup>58</sup>. Withdrawal of amiodarone can reverse blue–grey discoloration in some but not all patients, and pigmentation can take months or years to disappear. Other common cardiovascular drugs reported to cause phototoxicity include some angiotensin-converting enzyme inhibitors, angiotensin receptor blockers, dihydropyridine calcium channel blockers and statins, although the incidence of phototoxicity with these drugs is not well known<sup>53,59</sup>. Patients taking photosensitizing drugs should be counselled on sun protection, including wearing clothes with an ultraviolet protection factor of at least 30–50 and a broad-acting sunscreen that blocks both ultraviolet A and ultraviolet B.

Those with orthotopic heart transplants are another high-risk group for the development of skin cancers, including melanomas, squamous cell carcinomas and basal cell carcinomas, due to lifelong antirejection therapies, with 25–38% of patients developing non-melanoma skin cancer within 10 years of transplantation<sup>60–62</sup>. Rarely, Kaposi sarcoma can occur, with the highest risk after lung transplantation, but the overall risk has declined over time due to changes in immunosuppression regimens<sup>63,64</sup>. Heart–lung and heart transplant recipients (together with lung transplant recipients) develop skin cancer at higher rates than recipients of any other solid-organ transplant<sup>65</sup>. Expert consensus guidelines endorsed by the International Society for Heart and Lung Transplantation and the International Transplant Skin Cancer Collaborative recommend that all heart transplant recipients receive skin cancer screening from a dermatologist within 2–5 years of transplantation, with continued and individualized follow-up screening with a dermatologist. Heart transplant recipients with a history of skin cancer should immediately establish dermatologist care for individualized skin cancer screening. The guidelines also note that: “Ideally, transplant providers should ask patients about new skin complaints at every visit and refer promptly for evaluation if necessary”<sup>65</sup>. Although these guidelines do not specify screening intervals, skin cancer screening guidelines for other solid-organ (such as kidney or liver) transplant recipients with comparatively lower rates of skin cancer recommend annual screening<sup>66</sup>. Prediction models that include race/ethnicity, age, sex, history of skin cancer and type of transplant can be used to risk-stratify patients<sup>67</sup>.

### Chronic eczematous reactions

In older adults, the chronic use of calcium channel blockers or diuretics is associated with an increased risk of chronic eczematous skin reactions<sup>68–70</sup>. A longitudinal study of 1.5 million older adults found that patients who received diuretics or calcium channel blockers developed eczematous dermatitis with hazard ratios of 1.21 and 1.16, respectively, compared with patients who did not receive these medications, after adjusting for sociodemographic characteristics, health-care utilization and chronic kidney disease<sup>68</sup>. The mechanism for this reaction is not well understood but might be associated with drug-induced uptake and retention of iron in keratinocytes, causing spongiosis and desquamation<sup>71</sup>. These reactions present as widespread, persistent, intensely pruritic eczema-like rashes on the skin that develop several months after initiation of the responsible drug and can be difficult to treat. The skin reaction resolves in most patients after withdrawal of the drug, but others require further treatment, such as emollients, topical steroids, antihistamines or systemic treatments, for more severe cases<sup>70</sup>.

## Allergic and irritant contact dermatitis

Allergic and irritant contact dermatitis are, respectively, a type IV hypersensitivity reaction and a non-specific inflammatory response that can develop through repeated contact with external devices and artificial implants, including electrocardiogram electrodes, outpatient cardiac device monitors, adhesives, conductive gel or, rarely, cardiac rhythm devices. These reactions present as pruritus, erythema, oedema, crusting, vesicles or pustules at the site of contact, usually developing 24–72 h after exposure and reaching their peak at 72–96 h. Although nickel allergies are common, nickel found in electrocardiography electrodes is only rarely implicated in contact dermatitis<sup>72,73</sup>. Testing material on an unaffected area of skin is an expedient way to evaluate for contact dermatitis, and patch testing provides the most definitive diagnosis. Management includes substituting the offending material for an alternative if possible, or using a topical steroid spray before application of the device<sup>74</sup>. Rarely, allergic reactions to implanted cardiac devices (such as pacemakers or implantable cardioverter–defibrillators) can present with skin findings at the implantation site, such as erythema, oedema, pain or pruritus, and allergic reactions can be confirmed with positive patch tests. In these rare cases, extraction of the device might be necessary<sup>75,76</sup>. Coronary stent restenosis has been reported in patients with patch test-confirmed allergies to common stent metals, such as nickel and chromium, but larger, prospective studies are needed to determine whether metal allergies causally contribute to stent restenosis or whether metal allergies are common and incidental findings<sup>77</sup>.

## Niacin-associated skin toxicity

Niacin is associated with vasodilatation-induced flushing and redness of the skin, especially on initiation, which is reported in >60% of clinical trial participants, and results in drug discontinuation in 5–20% of individuals<sup>78</sup>. Although niacin is no longer commonly used to treat dyslipidaemia<sup>79</sup>, before niacin is initiated, patients should be counselled on the possibility of a flushing reaction and strategies to mitigate the reaction, including gradual dose escalation, taking the medication with food or taking a non-steroidal anti-inflammatory drug shortly before use<sup>80,81</sup>.

## Non-specific and rare cutaneous reactions

Almost any drug can produce reactions on the skin and it can be difficult for clinicians to account for all possible drug reactions. Rather than knowing all possible cutaneous reactions to all drugs, clinicians should be familiar with the most important and common reactions and ask patients about new adverse effects as part of routine medication monitoring. Non-specific cutaneous reactions to drugs, including morbilliform rashes and urticaria, can occur due to almost any drug, including hydrochlorothiazide, nitroglycerin, propranolol and spironolactone, usually at rates of <0.1%<sup>82</sup>. A wide range of rare but serious drug reactions have been reported in association with cardiovascular drugs, including: Stevens–Johnson syndrome and toxic epidermal necrolysis associated with diuretics<sup>83</sup>; acute generalized exanthematous pustulosis associated with diltiazem<sup>84</sup>; angioedema associated with angiotensin-converting enzyme inhibitors<sup>85,86</sup>; subacute cutaneous lupus erythematosus associated with calcium channel blockers, thiazide diuretics and angiotensin-converting enzyme inhibitors<sup>87</sup>; skin ulceration associated with nicorandil<sup>88,89</sup>; and skin necrosis associated with anticoagulants such as warfarin<sup>90</sup>. New skin signs should prompt clinicians to review the medication list for recently initiated medications and to consider referral to dermatology for evaluation.

## Cardiovascular effects of skin disease

### Psoriasis

Several inflammatory skin diseases have been associated with an increased risk of cardiovascular disease, with evidence being most extensive for psoriasis. Psoriasis is disease of the skin and joints mediated by T helper 1 and T helper 17 cells, and affects more than 60 million people worldwide<sup>91</sup>. Psoriasis is characterized by red, thick and scaly plaques that itch, crack and bleed. Psoriasis is associated with aortic and coronary artery inflammation, atherosclerosis (including coronary plaques with high-risk, lipid-rich necrotic cores), insulin resistance, diabetes, dyslipidaemia (including impaired HDL function and pro-atherogenic lipid profiles), chronic kidney disease, metabolic dysfunction-associated steatotic liver disease, myocardial infarction, stroke and cardiovascular death<sup>92–103</sup>. The risk of diabetes, cardiovascular disease and death increases with increasing surface area affected by psoriasis, and patients with moderate to severe psoriasis have a 5-year reduction in life expectancy, with excess cardiovascular death contributing the most to this reduction<sup>104,105</sup>.

The relationship between psoriasis and atherosclerotic vascular disease is thought to be multifactorial, involving shared environmental (infection, obesity and smoking) and genetic risk factors<sup>94,106</sup> (Fig. 1). Mendelian randomization studies suggest that the genetic factors associated with psoriasis might cause cardiovascular disease and that the genetic factors associated with coronary artery disease might cause psoriasis<sup>107,108</sup>. Rare variants in genes such as *CARD14*, *DDX58* and *IFIH1*, which encode proteins in the type I interferon and innate immunity pathways, have been implicated in cardiovascular disease, such as the monogenic Singleton–Merten syndrome (caused by variants in *DDX58* or *IFIH1*), which is associated with both valve and vascular calcification and psoriasis<sup>109–111</sup>.

The cutaneous inflammatory response in psoriasis closely parallels that which occurs in atherosclerosis. The upregulated pro-atherosclerotic cytokines present in lesional psoriatic skin include IL-6-related proteins, IL-8, interferon- $\gamma$  and TNF<sup>112</sup>. These proteins, as well as autoreactive CD4<sup>+</sup> and CD8<sup>+</sup> T cells, circulate systemically. The NLRP3 inflammasome signalling pathway (IL-1 $\beta$  to IL-6) is highly upregulated in psoriasis and has a causal role in atherosclerosis and cardiovascular events<sup>113–116</sup>. The role of IL-17 and IL-23, which are crucial cytokines in psoriasis, is less clear in atherosclerotic cardiovascular disease, in which studies indicate both pro-atherogenic and anti-atherogenic effects<sup>117</sup>. Both lymphocyte platelet aggregates and neutrophil platelet aggregates are increased in psoriatic disease, are present in psoriatic plaques and promote vascular endothelial damage<sup>118</sup>. Neutrophils predominate in psoriatic plaques and form neutrophil extracellular traps, potentially via interaction with platelets<sup>119</sup>, and a similar process also occurs in atherosclerosis via stimulation by NLRP3 inflammasome mediators<sup>120</sup>.

In vivo studies show that the same microvascular endothelial cell inflammation present in the skin of patients with psoriasis is also present in the microvasculature of other tissues<sup>113</sup>, and the degree of psoriatic activity directly correlates with arterial macrophage metabolic activity<sup>99</sup>. Oxidized lipid mediators are present in psoriatic skin<sup>121</sup>, and the circulating levels of both oxidized LDL and HDL are associated with the extent of atherosclerotic plaque in patients with psoriasis<sup>122</sup>. Cathelicidin antimicrobial peptide LL-37 is produced by psoriatic skin in humans and increases LDL uptake in macrophages and the development of atherosclerosis<sup>123</sup>. Visceral but not subcutaneous adipose tissue secretes cytokines such as TNF, and the levels of this cytokine directly correlate with psoriatic disease activity and vascular inflammation<sup>124,125</sup>. Insulin resistance is associated with psoriasis and

perpetuates a systemic pro-inflammatory state, given that advanced glycosylation end products are seen in the skin and serum of patients with psoriasis<sup>126</sup>. Elevated circulating triglyceride levels have been shown to be a causal risk factor for psoriasis<sup>127</sup>. Additional pathophysiological connections include epidermal proliferation in psoriasis, which promotes an oxidative state and hyperuricaemia, as well as chronic angiogenesis, with circulating levels of vascular endothelial growth factor correlating with psoriasis severity<sup>128,129</sup>.

Advances in genetics, immunology, cardiovascular imaging, medical informatics and epidemiology have redefined psoriasis as a systemic disease with substantial cardiometabolic morbidity and mortality<sup>92</sup>. In psoriasis, traditional cardiovascular risk factors act synergistically with an already primed and dysregulated immune system to promote cardiovascular disease<sup>92,94</sup>. Cardiology guidelines in the USA identify psoriasis as a cardiovascular risk enhancer that necessitates earlier and more intensive prevention and treatment of cardiovascular risks<sup>79</sup>. Dermatology guidelines in the USA also recommend earlier and more intensive screening of cardiovascular risks in patients with psoriasis<sup>92</sup>. Similar guidelines for cardiovascular screening in psoriasis have been published by dermatology and cardiology societies worldwide, including in Europe<sup>130</sup>, Spain<sup>131</sup>, Taiwan<sup>132</sup> and the UK<sup>133</sup>, with slight variations in recommendations for screening frequency and risk calculation.

Despite broad recognition of the importance of cardiovascular risk management in this population, cardiovascular risk factors in patients with psoriasis are under-screened and under-managed by both primary care providers and specialists<sup>134–136</sup>. New approaches from the field of implementation science are being studied to narrow this evidence-to-practice gap, with the involvement of care coordinators showing promise<sup>137</sup>.

## Emerging evidence in other skin diseases

Emerging evidence suggests that several other primary skin diseases can also be associated with adverse cardiovascular outcomes and diseases, including atopic dermatitis, hidradenitis suppurativa, rosacea, alopecia areata and androgenetic alopecia (Table 2). Further studies are needed to confirm these associations and to discern whether these skin diseases and signs causally affect cardiovascular health or are markers of worse cardiovascular health.

## Cardiometabolic effects of dermatological treatment

Therapies commonly used for dermatological diseases can have beneficial or harmful effects on the cardiovascular and cardiometabolic systems (Table 3). In general, many of the associations found in observational studies of these therapies require further investigation to establish causality and uncover possible mechanisms.

### Apremilast

Apremilast is a small-molecular inhibitor of phosphodiesterase 4 used to treat psoriasis, psoriatic arthritis and Behçet disease and is associated with weight loss. A clinical trial demonstrated that patients with psoriasis taking apremilast have a 5–6% reduction in visceral adiposity that is maintained for 52 weeks, with improvement in aortic vascular inflammation in those with increased levels at baseline<sup>138</sup>.

### Ciclosporin

Ciclosporin is a calcineurin inhibitor and immunosuppressive agent that is sometimes used to treat severe psoriasis and severe atopic

dermatitis, among other indications. Adverse effects of ciclosporin include hypertension and nephrotoxicity<sup>139</sup>. Hypertension can be managed with a reduction in ciclosporin dose or with antihypertensive medication. Because ciclosporin is associated with nephrotoxicity and is thought to produce vasoconstriction in the renal arterioles, calcium channel blockers are preferred because they relax vascular smooth muscle. Conversely, thiazide diuretics and potassium-sparing diuretics should be avoided due to the risk of potentiated nephrotoxicity and hyperkalaemia, respectively<sup>139</sup>. Ciclosporin is also extensively metabolized by cytochrome P450 3A4, and relevant drug interactions should be considered. For example, because co-administration of certain statins and ciclosporin can produce many-fold increases in statin bioavailability and cases of rhabdomyolysis, the American Heart Association recommends avoiding certain statins (lovastatin, pitavastatin and simvastatin) and carefully considering lower doses of other statins (atorvastatin, fluvastatin, pravastatin and rosuvastatin) in patients taking ciclosporin<sup>140</sup>.

### Colchicine

Colchicine is used for a variety of neutrophilic skin diseases including Sweet syndrome, leukocytoclastic vasculitis and pyoderma gangrenosum. Colchicine is approved in the USA to reduce the risk of myocardial infarction, stroke, coronary revascularization and cardiovascular death in adult patients with established atherosclerotic disease or with multiple risk factors for cardiovascular disease<sup>141</sup>.

### IL-12 and IL-23 inhibitors

The monoclonal antibody ustekinumab targets IL-12 and IL-23 and is used to treat psoriasis and other conditions such as inflammatory bowel disease. In early clinical trials of ustekinumab and another inhibitor of IL-12 and IL-23, briakinumab, a potential safety signal for triggering major cardiovascular events was observed<sup>142</sup>. A case–crossover study of ustekinumab showed an increased risk of cardiovascular events within the first 6 months of treatment; however, this finding was sensitive to definitions of duration of ustekinumab use and its interpretation was limited by the study design<sup>143,144</sup>. The majority of observational studies and phase II and phase III placebo-controlled clinical trials have shown no evidence of adverse cardiovascular effects of this agent<sup>145–147</sup>. In a randomized, placebo-controlled trial, ustekinumab reduced aortic vascular inflammation in patients with psoriasis compared with placebo at 12 weeks, but the effect was not maintained at 52 weeks<sup>148</sup>. The EMA recommends that risk factors for cardiovascular disease should be regularly assessed during treatment with ustekinumab<sup>149</sup>.

### JAK family inhibitors

Janus kinase (JAK) family inhibitors, including abrocitinib, baricitinib, deuruxolitinib, ritlecitinib, ruxolitinib (topical), tofacitinib and upadacitinib, are a new class of immunomodulating drugs used to treat severe atopic dermatitis, alopecia areata, psoriatic disease and vitiligo, among other autoimmune diseases. Regulatory agencies in the European Union, UK and USA warn of adverse cardiovascular events associated with the use of JAK inhibitors<sup>150–152</sup>, primarily based on a large, randomized trial in patients with active rheumatoid arthritis who were aged ≥50 years and had at least one additional cardiovascular risk factor, which demonstrated that the risk of major adverse cardiovascular events was higher with tofacitinib than with TNF inhibitors<sup>153</sup>. By contrast, a meta-analysis of short-term follow-up from phase III trials of JAK inhibitors for dermatological conditions found no increase in the risk of major adverse cardiovascular events, venous thromboembolism



Table 2 | Primary skin diseases with cardiovascular and cardiometabolic associations

Skin disease	Clinical images	Skin features	Prevalence	Cardiovascular and cardiometabolic associations
Psoriasis		Red, thick, well-demarcated, scaly plaques that can itch, crack and bleed	2–3% in the USA <sup>191,192</sup>	Well-established association with atherosclerosis, insulin resistance and diabetes mellitus, chronic kidney disease, metabolic dysfunction-associated steatotic liver disease, myocardial infarction, stroke and cardiovascular mortality <sup>92–103</sup>
Atopic dermatitis		Erythematous papules and vesicles, often with crusting or weeping; in the long term, can develop scale, excoriations and lichenification; follicular accentuation and hyperpigmentation are more common in darker skin	6–13% in the USA and up to 23% globally <sup>193</sup>	Emerging evidence of clotting dysfunction (venous thromboembolism and cardiovascular disease, including myocardial infarction, stroke, pulmonary embolism and early cardiovascular mortality) in those with moderate to severe atopic dermatitis <sup>194–199</sup>
Hidradenitis suppurativa		Recurrent, malodorous and painful abscesses in areas of skin rich in apocrine sweat glands (axillae, groin and submammary areas)	0.3–1.7% in American and European populations <sup>200</sup>	Emerging evidence of myocardial infarction, ischaemic stroke, major cardiovascular events, cardiovascular mortality and all-cause mortality <sup>201–203</sup>
Rosacea		Flushing, erythema, telangiectasia, papules and pustules, oedema and/or pain, often symmetrically affecting the central face, nose and cheeks	5.5% globally <sup>204</sup>	Emerging evidence of hypertension, dyslipidaemia, metabolic syndrome <sup>205</sup> and coronary heart disease <sup>206</sup>



Table 2 (continued) | Primary skin diseases with cardiovascular and cardiometabolic associations



Skin disease	Clinical images	Skin features	Prevalence	Cardiovascular and cardiometabolic associations
Alopecia areata		Round, well-circumscribed, bald patches with smooth surfaces and total hair loss	0.6–3.8% globally <sup>207</sup>	Emerging evidence of coronary artery disease, metabolic syndrome and hyperinsulinaemia <sup>208</sup>
Androgenetic alopecia		In men, recession of frontal hairline and vertex thinning of the scalp; in women, diffuse thinning of the central and parietal regions of the scalp	Very common, increasing with age	Some evidence for dyslipidaemia <sup>209</sup> and coronary heart disease <sup>210</sup>

Image of psoriasis courtesy of J. M. Gelfand. All other images reproduced with permission from VisualDx.

or all-cause death compared with placebo or active comparator<sup>154</sup>. JAK inhibitors also induce changes in lipid levels: one meta-analysis found that JAK inhibitor use in patients with rheumatoid arthritis was associated with a mean increase in plasma LDL and HDL levels by 11.4 mg/dl and 8.1 mg/dl, respectively, without a clear associated effect on the overall risk of cardiovascular disease<sup>155</sup>.

Methotrexate

Methotrexate has been used for decades to treat psoriasis and other inflammatory diseases. Observational data in patients with rheumatoid arthritis or psoriasis suggest that methotrexate reduces the incidence of cardiovascular events, but a trial of methotrexate in patients with a previous myocardial infarction or multivessel coronary artery disease with either type 2 diabetes or metabolic syndrome showed no evidence of benefit on atherosclerotic cardiovascular disease<sup>156</sup>.

Minoxidil

Low-dose oral minoxidil is a peripheral vasodilator that has gained popularity in the treatment of androgenetic alopecia<sup>157</sup>, although the drug is not currently FDA-approved for this indication (whereas topical minoxidil is approved). For hair loss, a dose of 0.25–5.00 mg per day is typically used, compared with the effective dose range of 10–40 mg per day, with a 100 mg per day maximum dose, that is recommended by the FDA for hypertension<sup>158–160</sup>. At low doses, oral minoxidil is still associated with cardiovascular adverse effects, including orthostatic hypotension, fluid retention and oedema, and sinus tachycardia. A single-group, retrospective study including 1,404 patients from

ten clinical centres in six countries who received low-dose oral minoxidil for any hair loss found that each of these cardiovascular adverse effects occurred at rates of 1–3% and in a dose-dependent manner<sup>158</sup>, consistent with findings of previous systematic reviews<sup>159</sup>. These adverse effects can require additional medical management if the patient chooses to continue the medication<sup>158</sup>. Low-dose oral minoxidil does not seem to be associated with certain severe adverse effects observed with higher doses of minoxidil, such as pericardial effusions<sup>158–160</sup>.

Retinoids

Retinoids, including acitretin, bexarotene and isotretinoin, are used in patients with psoriasis, cutaneous T cell lymphoma and acne, respectively. Many patients using oral retinoids develop new or worse dyslipidaemia, especially hypertriglyceridaemia<sup>161</sup>. These changes are usually mild. However, approximately 1.5% of patients using isotretinoin develop plasma triglyceride levels of >400 mg/dl, and rare cases of pancreatitis have been reported in clinical trials<sup>162,163</sup>.

TNF inhibitors

The monoclonal antibodies adalimumab, certolizumab, etanercept and infliximab are TNF inhibitors used to treat psoriasis and hidradenitis suppurativa, among other inflammatory immune-mediated diseases. Based on pathophysiology, TNF inhibitors were hypothesized to be effective in treating heart failure, but a randomized, placebo-controlled trial of intravenous infliximab in patients with New York Heart Association class III–IV heart failure and a left ventricular ejection fraction of ≤35% demonstrated an increased combined risk

of hospitalization for heart failure or all-cause death in the high-dose (10 mg/kg) group<sup>164</sup>. However, a subcutaneous TNF inhibitor (etanercept) did not show adverse cardiovascular effects in two other trials in patients with heart failure<sup>165</sup>. Observational data suggest that TNF inhibitors are associated with a reduction in the rate of myocardial infarction in patients with immune-mediated disease<sup>166,167</sup>, and randomized, controlled trial data in patients with psoriasis show that TNF inhibitors reduce the levels of biomarkers of cardiovascular risk, including IL-6, C-reactive protein and glycoprotein acetyls<sup>168,169</sup>. However, randomized, controlled trials specifically assessing the effect of TNF inhibitors on cardiovascular outcomes in patients with inflammatory diseases are lacking.

## Ultraviolet phototherapy

Ultraviolet B phototherapy is used for a variety of skin disorders and has been shown to reduce the plasma levels of C-reactive protein and IL-6, and to increase the plasma levels of HDL particles in patients with psoriasis<sup>169</sup>. Low-dose ultraviolet A phototherapy transiently lowers blood pressure in patients with mild hypertension<sup>170</sup>. Natural sunlight exposure is associated with a reduction in atherosclerotic disease, blood pressure and cardiovascular mortality in observational studies, but these findings might be confounded by other behaviours, such as exercise<sup>171–173</sup>. Additional research is necessary before ultraviolet radiation can be recommended for the prevention or treatment of cardiovascular disease.

**Table 3 | Effects of dermatological treatments on cardiovascular and cardiometabolic disease**

Treatment	Class and dermatological indications	Cardiovascular and cardiometabolic effects
Apremilast	Small-molecular inhibitor of phosphodiesterase 4 used for psoriasis, psoriatic arthritis and Behçet disease	Associated with weight loss and reduction in visceral adiposity <sup>138</sup>
Ciclosporin	Calcineurin inhibitor used for severe psoriasis and severe eczema	Hypertension and nephrotoxicity <sup>139</sup> ; hypertension can be managed with dose reduction or antihypertensive medication (preferably calcium channel blockers, whereas thiazide diuretics and potassium-sparing diuretics should be avoided); ciclosporin is extensively metabolized by cytochrome P450 3A4, and interactions with relevant drugs such as statins should be considered
Colchicine	Anti-mitotic alkaloid used for neutrophilic skin diseases, including Sweet syndrome, leukocytoclastic vasculitis and pyoderma gangrenosum	Approved in the USA to reduce the risk of myocardial infarction, stroke, coronary revascularization and cardiovascular death in adult patients with established atherosclerotic disease or with multiple risk factors for cardiovascular disease <sup>141</sup>
IL-12 and IL-23 inhibitors	Monoclonal antibody inhibiting IL-12 and IL-23 used for psoriasis	Mixed evidence on risk of cardiovascular events, with most observational studies and phase II–III clinical trials showing no evidence of adverse cardiovascular effects <sup>143–147</sup> ; the EMA recommends that risk factors for cardiovascular disease should be regularly assessed during treatment with ustekinumab <sup>149</sup>
JAK inhibitors	Inhibitors of JAK and signal transducer and activator of transcription signalling pathways used for severe atopic dermatitis, alopecia areata, psoriatic disease and vitiligo and a wide range of other immune-mediated inflammatory diseases	Regulatory agencies in the European Union, UK and USA warn of adverse cardiovascular events associated with JAK inhibitors <sup>150–152</sup> , although a meta-analysis of phase III trials of JAK inhibitors for dermatological conditions found no increased risk of major adverse cardiovascular events, venous thromboembolism or all-cause death compared with placebo or comparator groups <sup>154</sup> ; JAK inhibitors can alter plasma lipid levels, based on studies in rheumatoid arthritis <sup>155</sup>
Methotrexate	Antifolate disease-modifying anti-rheumatic drug used for psoriatic disease	Observational data in rheumatoid arthritis and psoriasis suggest that methotrexate reduces cardiovascular events, but a trial of methotrexate in patients with a previous myocardial infarction or multivessel coronary disease who additionally had either type 2 diabetes mellitus or metabolic syndrome showed no evidence of benefit in atherosclerotic cardiovascular disease <sup>156</sup>
Minoxidil	Peripheral vasodilator used for androgenetic alopecia	Low-dose (0.25–5.00 mg per day) oral minoxidil, which has gained popularity for androgenetic alopecia although it is not approved by the FDA for this indication, is associated with orthostatic hypotension, fluid retention and oedema, and tachycardia at rates of 1–3% and in a dose-dependent manner <sup>158</sup> , but does not seem to be associated with the severe adverse effects that are observed with higher doses of minoxidil, such as pericardial effusions <sup>158–160</sup>
Retinoids	Vitamin A derivatives used topically or systemically for cutaneous T cell lymphoma, psoriasis and acne	Risk of mild dyslipidaemia and rare risk of severe hypertriglyceridaemia or pancreatitis <sup>161–163</sup>
TNF inhibitors	Monoclonal antibodies inhibiting TNF used for psoriasis and hidradenitis suppurativa and a wide range of other immune-mediated inflammatory diseases	A randomized, placebo-controlled trial of intravenous infliximab to treat heart failure found an increased combined risk of hospitalization for heart failure or all-cause death at high doses (10 mg/kg), whereas two randomized, controlled trials for heart failure showed that subcutaneous etanercept had no significant effect on similar outcomes <sup>164,165</sup> ; observational data suggest that TNF inhibitors are associated with a reduction in myocardial infarction in patients with immune-mediated disease <sup>166,167</sup>
Ultraviolet light therapy	Ultraviolet light for psoriasis, eczema, prurigo nodularis, cutaneous T cell lymphoma, vitiligo and many other dermatological indications	In psoriasis, ultraviolet B therapy has been shown to reduce plasma levels of IL-6 and C-reactive protein and increase plasma levels of HDL particles <sup>169</sup> ; low-dose ultraviolet A therapy transiently lowers blood pressure in patients with mild hypertension <sup>170</sup> ; natural sunlight exposure is associated with a reduction in atherosclerotic disease, blood pressure and cardiovascular death in observational studies <sup>171–173</sup>

JAK, Janus kinase; TNF, tumour necrosis factor.

## Conclusions

Skin structure and function have a crucial role in health and disease. Recognition of common and rare skin conditions relevant to cardiology provides an opportunity for clinical cardiologists to improve outcomes in patients. Future studies are needed to define the cardiovascular effects of emerging dermatological therapeutics. Close collaboration between dermatologists, cardiologists, clinical scientists and basic research scientists will be crucial for advancing our knowledge of the complex interaction between the skin and the cardiovascular system, so that individual and population health can be improved.

Published online: 13 November 2024

## References

- Guttman-Yassky, E., Zhou, L. & Krueger, J. G. The skin as an immune organ: tolerance versus effector responses and applications to food allergy and hypersensitivity reactions. *J. Allergy Clin. Immunol.* **144**, 362–374 (2019).
- Clark, R. A. et al. The vast majority of CLA<sup>+</sup> T cells are resident in normal skin. *J. Immunol.* **176**, 4431–4439 (2006).
- Vu, T. T., Koguchi-Yoshioka, H. & Watanabe, R. Skin-resident memory T cells: pathogenesis and implication for the treatment of psoriasis. *J. Clin. Med.* **10**, 3822 (2021).
- Tamari, M., Ver Heul, A. M. & Kim, B. S. Immunosensation: neuroimmune cross talk in the skin. *Annu. Rev. Immunol.* **39**, 369–393 (2021).
- Charkoudian, N. Skin blood flow in adult human thermoregulation: how it works, when it does not, and why. *Mayo Clin. Proc.* **78**, 603–612 (2003).
- Kim, B. et al. Neuroimmune interplay during type 2 inflammation: symptoms, mechanisms, and therapeutic targets in atopic diseases. *J. Allergy Clin. Immunol.* **153**, 879–893 (2023).
- Johnson, K. E. & Wilgus, T. A. Vascular endothelial growth factor and angiogenesis in the regulation of cutaneous wound repair. *Adv. Wound Care (N. Rochelle)* **3**, 647–661 (2014).
- Feingold, K. R. The outer frontier: the importance of lipid metabolism in the skin. *J. Lipid Res.* **50**, S417–S422 (2009).
- Jara, C. P., Mendes, N. F., do Prado, T. P. & de Araujo, E. P. Bioactive fatty acids in the resolution of chronic inflammation in skin wounds. *Adv. Wound Care (N. Rochelle)* **9**, 472–490 (2020).
- Bertola, E. A. et al. Extrarenal immune-mediated disorders linked with acute poststreptococcal glomerulonephritis: a systematic review. *Clin. Rev. Allergy Immunol.* **57**, 294–302 (2019).
- Muhammed, B., Parks, T. & Sliwa, K. Genetics of rheumatic fever and rheumatic heart disease. *Nat. Rev. Cardiol.* **17**, 145–154 (2020).
- Carapetis, J. R. et al. Acute rheumatic fever and rheumatic heart disease. *Nat. Rev. Dis. Prim.* **2**, 15084 (2016).
- Piette, W. W. in *Fitzpatrick's Dermatology* 9th edn Ch. 66 (eds Kang, S. et al.) (McGraw-Hill, 2019).
- D'Aguanno, V. et al. Systemic amyloidosis: a contemporary overview. *Clin. Rev. Allergy Immunol.* **59**, 304–322 (2020).
- Merlini, G., Seldin, D. C. & Gertz, M. A. Amyloidosis: pathogenesis and new therapeutic options. *J. Clin. Oncol.* **29**, 1924–1933 (2011).
- Horvath, A. & Stratakis, C. A. Carney complex and lentiginosis. *Pigment. Cell Melanoma Res.* **22**, 580–587 (2009).
- Pitsava, G., Zhu, C., Sundaram, R., Mills, J. L. & Stratakis, C. A. Predicting the risk of cardiac myxoma in Carney complex. *Genet. Med.* **23**, 80–85 (2021).
- Malfait, F. et al. The Ehlers–Danlos syndromes. *Nat. Rev. Dis. Prim.* **6**, 64 (2020).
- Zilocchi, M. et al. Vascular Ehlers–Danlos syndrome: imaging findings. *AJR Am. J. Roentgenol.* **189**, 712–719 (2007).
- Shabani, M. et al. Vascular aneurysms in Ehlers–Danlos syndrome subtypes: a systematic review. *Clin. Genet.* **103**, 261–267 (2023).
- D'Hondt, S., Van Damme, T. & Malfait, F. Vascular phenotypes in nonvascular subtypes of the Ehlers–Danlos syndrome: a systematic review. *Genet. Med.* **20**, 562–573 (2018).
- van de Laar, I. et al. Surveillance and monitoring in vascular Ehlers–Danlos syndrome in European Reference Network For Rare Vascular Diseases (VASCERN). *Eur. J. Med. Genet.* **65**, 104557 (2022).
- Ong, K. T. et al. Effect of celiprolol on prevention of cardiovascular events in vascular Ehlers–Danlos syndrome: a prospective randomised, open, blinded-endpoints trial. *Lancet* **376**, 1476–1484 (2010).
- Frank, M. et al. Vascular Ehlers–Danlos syndrome: long-term observational study. *J. Am. Coll. Cardiol.* **73**, 1948–1957 (2019).
- Baderkhan, H., Wanhainen, A., Stenborg, A., Stattin, E. L. & Björck, M. Celiprolol treatment in patients with vascular Ehlers–Danlos syndrome. *Eur. J. Vasc. Endovasc. Surg.* **61**, 326–331 (2021).
- De Backer, J. & De Backer, T. Vascular Ehlers–Danlos syndrome management: the Paris way, a step forward on a long road. *J. Am. Coll. Cardiol.* **73**, 1958–1960 (2019).
- Murdoch, D. R. et al. Clinical presentation, etiology, and outcome of infective endocarditis in the 21st century: the International Collaboration on Endocarditis-Prospective Cohort Study. *Arch. Intern. Med.* **169**, 463–473 (2009).
- Habib, G. et al. Clinical presentation, aetiology and outcome of infective endocarditis. Results of the ESC-EORP EURO-ENDO (European Infective Endocarditis) registry: a prospective cohort study. *Eur. Heart J.* **40**, 3222–3232 (2019).
- McCordle, B. W. et al. Diagnosis, treatment, and long-term management of Kawasaki disease: a scientific statement for health professionals from the American Heart Association. *Circulation* **135**, e927–e999 (2017).
- Noval Rivas, M. & Arditi, M. Kawasaki disease: pathophysiology and insights from mouse models. *Nat. Rev. Rheumatol.* **16**, 391–405 (2020).
- Watanabe, Y., Ikeda, H. & Watanabe, T. Differences in the clinical characteristics of Kawasaki disease between older and younger children (2015–2019): a single-center, retrospective study. *J. Pediatr.* **253**, 266–269 (2023).
- Saundankar, J. et al. The epidemiology and clinical features of Kawasaki disease in Australia. *Pediatrics* **133**, e1009–e1014 (2014).
- Sanchez-Manubens, J., Bou, R. & Anton, J. Diagnosis and classification of Kawasaki disease. *J. Autoimmun.* **48–49**, 113–117 (2014).
- Rowley, A. H. in *Fitzpatrick's Dermatology* 9th edn Ch. 142 (eds Kang, S. et al.) (McGraw-Hill, 2019).
- Fukazawa, R. et al. JCS/JSCS 2020 guideline on diagnosis and management of cardiovascular sequelae in Kawasaki disease. *Circ. J.* **84**, 1348–1407 (2020).
- Green, J., Wardle, A. J. & Tulloh, R. M. Corticosteroids for the treatment of Kawasaki disease in children. *Cochrane Database Syst. Rev.* **5**, CD011188 (2022).
- Kabbaha, S., Milano, A., Aldeyab, M. A. & Thorlund, K. Infliximab as a second-line therapy for children with refractory Kawasaki disease: a systematic review and meta-analysis of randomized controlled trials. *Br. J. Clin. Pharmacol.* **89**, 49–60 (2023).
- Newman, S. A. in *Fitzpatrick's Dermatology* 9th edn Ch. 148 (eds Kang, S. et al.) (McGraw-Hill, 2019).
- Lioncino, M. et al. Hypertrophic cardiomyopathy in rasopathies: diagnosis, clinical characteristics, prognostic implications, and management. *Heart Fail Clin.* **18**, 19–29 (2022).
- Sarkozy, A. et al. Clinical and molecular analysis of 30 patients with multiple lentigines LEOPARD syndrome. *J. Med. Genet.* **41**, e68 (2004).
- Limongelli, G. et al. Prevalence and clinical significance of cardiovascular abnormalities in patients with the LEOPARD syndrome. *Am. J. Cardiol.* **100**, 736–741 (2007).
- Rocha, L. K. et al. Cutaneous manifestations and comorbidities in 60 cases of Takayasu arteritis. *J. Rheumatol.* **40**, 734–738 (2013).
- Frances, C. et al. Cutaneous manifestations of Takayasu arteritis. A retrospective study of 80 cases. *Dermatologica* **181**, 266–272 (1990).
- Weber, B. N. et al. Acute cardiovascular complications of immune-mediated systemic inflammatory diseases. *Eur. Heart J. Acute Cardiovasc. Care* **12**, 792–801 (2023).
- Merkel, P. A. & Monach, P. A. in *Fitzpatrick's Dermatology* 9th edn Ch. 139 (eds Kang, S. et al.) (McGraw-Hill, 2019).
- Soura, E. in *Skin and the Heart* Ch. 17 (eds Salavastu, C., Murrell, D. F. & Otton, J.) 267–282 (Springer, 2021).
- Sathiyakumar, V., Jones, S. R. & Martin, S. S. in *Fitzpatrick's Dermatology* 9th edn Ch. 126 (eds Kang, S. et al.) (McGraw-Hill, 2019).
- Roy, A., Kamalanathan, S., Naik, D. & Sahoo, J. P. Extensive tendon and tuberous xanthomas in a patient with familial hypercholesterolaemia. *BMJ Case Rep.* **13**, e236759 (2020).
- Agirbasli, D., Hyatt, T. & Agirbasli, M. Familial hypercholesterolemia with extensive coronary artery disease and tuberous and tendinous xanthomas: a case report and mutation analysis. *J. Clin. Lipidol.* **12**, 863–867 (2018).
- Maskey, A., Hirachan, A., Yadav, D. & Roka, M. Large multiple tuberous xanthomas presenting with severe coronary artery disease. *Eur. Heart J.* **38**, 2313 (2017).
- Civeira, F. et al. Tendon xanthomas in familial hypercholesterolemia are associated with cardiovascular risk independently of the low-density lipoprotein receptor gene mutation. *Arterioscler. Thromb. Vasc. Biol.* **25**, 1960–1965 (2005).
- Oosterveer, D. M., Versmissen, J., Yazdanpanah, M., Hamza, T. H. & Sijbrands, E. J. Differences in characteristics and risk of cardiovascular disease in familial hypercholesterolemia patients with and without tendon xanthomas: a systematic review and meta-analysis. *Atherosclerosis* **207**, 311–317 (2009).
- Kowalska, J., Rok, J., Rzepka, Z. & Wrzesniok, D. Drug-induced photosensitivity – from light and chemistry to biological reactions and clinical symptoms. *Pharmaceuticals* **14**, 723 (2021).
- Shao, S. C. et al. Associations of thiazide use with skin cancers: a systematic review and meta-analysis. *BMC Med.* **20**, 228 (2022).
- Vassallo, P. & Trohman, R. G. Prescribing amiodarone: an evidence-based review of clinical indications. *JAMA* **298**, 1312–1322 (2007).
- Fernandez-Flores, A. et al. Pigmented deposits in the skin. *Am. J. Dermatopathol.* **40**, 307–328 (2018).
- Rappersberger, K. et al. Photosensitivity and hyperpigmentation in amiodarone-treated patients: incidence, time course, and recovery. *J. Invest. Dermatol.* **93**, 201–209 (1989).
- Kaur, A., Mehta, D., Mahmood, K. & Tamis-Holland, J. A rare case of blue-gray discoloration induced by low-dose amiodarone. *Am. J. Cardiol.* **189**, 119–120 (2023).
- Gotzinger, F. et al. Photoinduced skin reactions of cardiovascular drugs – a systematic review. *Eur. Heart J. Cardiovasc. Pharmacother.* **8**, 420–430 (2022).
- Bakir, N. H. et al. Characterization of de novo malignancy after orthotopic heart transplantation: single-centre outcomes over 20 years. *Eur. J. Cardiothorac. Surg.* **64**, eza341 (2023).



61. Brewer, J. D. et al. Incidence of and risk factors for skin cancer after heart transplant. *Arch. Dermatol.* **145**, 1391–1396 (2009).
62. Adamson, R. et al. High incidence and clinical course of aggressive skin cancer in heart transplant patients: a single-center study. *Transpl. Proc.* **30**, 1124–1126 (1998).
63. Serlin, T. et al. Trends in Kaposi's sarcoma morbidity: a retrospective cohort study of heart and lung transplant recipients. *Acta Derm. Venereol.* **101**, adv00528 (2021).
64. Cahoon, E. K. et al. Risk of Kaposi sarcoma after solid organ transplantation in the United States. *Int. J. Cancer* **143**, 2741–2748 (2018).
65. Crow, L. D. et al. Initial skin cancer screening for solid organ transplant recipients in the United States: Delphi method development of expert consensus guidelines. *Transpl. Int.* **32**, 1268–1276 (2019).
66. Berman, H. et al. Skin cancer in solid organ transplant recipients: a review for the nondermatologist. *Mayo Clin. Proc.* **97**, 2355–2368 (2022).
67. Gómez-Tomás, Á. et al. External validation of the skin and UV neoplasia transplant risk assessment calculator (SUNTRAC) in a large European solid organ transplant recipient cohort. *JAMA Dermatol.* **159**, 29–36 (2023).
68. Ye, M. et al. Antihypertensive medications and eczematous dermatitis in older adults. *JAMA Dermatol.* **160**, 710–716 (2024).
69. Summers, E. M. et al. Chronic eczematous eruptions in the aging: further support for an association with exposure to calcium channel blockers. *JAMA Dermatol.* **149**, 814–818 (2013).
70. Joly, P. et al. Chronic eczematous eruptions of the elderly are associated with chronic exposure to calcium channel blockers: results from a case-control study. *J. Invest. Dermatol.* **127**, 2766–2771 (2007).
71. Gruen, A. B., Zhou, J., Morton, K. A. & Milstone, L. M. Photodegraded nifedipine stimulates uptake and retention of iron in human epidermal keratinocytes. *J. Invest. Dermatol.* **116**, 774–777 (2001).
72. Özkaya, E. & Kavlak Bozkurt, P. Allergic contact dermatitis caused by self-adhesive electrocardiography electrodes: a rare case with concomitant roles of nickel and acrylates. *Contact Dermat.* **70**, 121–123 (2014).
73. Warshaw, E. M. et al. Epidemiology of nickel sensitivity: retrospective cross-sectional analysis of North American Contact Dermatitis Group data 1994–2014. *J. Am. Acad. Dermatol.* **80**, 701–713 (2019).
74. Turrentine, J. E., Sheehan, M. P. & Cruz, P. D. Jr. in *Fitzpatrick's Dermatology* 9th edn Ch. 24 (eds Kang, S. et al.) (McGraw-Hill, 2019).
75. Gold, M., Nath, N., Green, C. & Atwater, A. R. Frequency of contact allergy to implanted cardiac devices. *JAMA Dermatol.* **155**, 749–752 (2019).
76. Honari, G. et al. Hypersensitivity reactions associated with endovascular devices. *Contact Dermat.* **59**, 7–22 (2008).
77. Hu, W. & Jiang, J. Hypersensitivity and in-stent restenosis in coronary stent materials. *Front. Bioeng. Biotechnol.* **10**, 1003322 (2022).
78. Jacobson, T. A. A “hot” topic in dyslipidemia management – “how to beat a flush”: optimizing niacin tolerability to promote long-term treatment adherence and coronary disease prevention. *Mayo Clin. Proc.* **85**, 365–379 (2010).
79. Grundy, S. M. et al. 2018 AHA/ACC/AACVPR/AAPA/ABC/ACPM/ADA/AGS/APHA/ASPC/NLA/PCNA guideline on the management of blood cholesterol: a report of the American College of Cardiology/American Heart Association Task Force on Clinical Practice Guidelines. *Circulation* **139**, e1082–e1143 (2019).
80. Guyton, J. R. & Bays, H. E. Safety considerations with niacin therapy. *Am. J. Cardiol.* **99**, 22C–31C (2007).
81. Dunbar, R. L. & Gelfand, J. M. Seeing red: flushing out instigators of niacin-associated skin toxicity. *J. Clin. Invest.* **120**, 2651–2655 (2010).
82. Bigby, M. Rates of cutaneous reactions to drugs. *Arch. Dermatol.* **137**, 765–770 (2001).
83. Wang, L. et al. Stevens–Johnson syndrome and toxic epidermal necrolysis: a systematic review of PubMed/MEDLINE case reports from 1980 to 2020. *Front. Med.* **9**, 949520 (2022).
84. Kim, H. J. et al. Acute generalized exanthematous pustulosis caused by diltiazem. *Ann. Dermatol.* **23**, 108–110 (2011).
85. Makani, H. et al. Meta-analysis of randomized trials of angioedema as an adverse event of renin-angiotensin system inhibitors. *Am. J. Cardiol.* **110**, 383–391 (2012).
86. Mahmoudpour, S. H. et al. Determinants of angiotensin-converting enzyme inhibitor (ACEI) intolerance and angioedema in the UK Clinical Practice Research Datalink. *Br. J. Clin. Pharmacol.* **82**, 1647–1659 (2016).
87. Lowe, G. C., Henderson, C. L., Grau, R. H., Hansen, C. B. & Sontheimer, R. D. A systematic review of drug-induced subacute cutaneous lupus erythematosus. *Br. J. Dermatol.* **164**, 465–472 (2011).
88. Lee, M. T. et al. Risk of skin ulcerations associated with oral nicorandil therapy: a population-based study. *Br. J. Dermatol.* **173**, 498–509 (2015).
89. Smith, V. M. & Lyon, C. C. Nicorandil: do the dermatological and gastrointestinal risks outweigh the benefits? *Br. J. Dermatol.* **167**, 1048–1052 (2012).
90. Moran-Marinos, C., Corcuera-Ciudad, R., Velasquez-Rimachi, V. & Nieto-Gutierrez, W. Systematic review of warfarin-induced skin necrosis case reports and secondary analysis of factors associated with mortality. *Int. J. Clin. Pract.* **75**, e15001 (2021).
91. Parisi, R. et al. National, regional, and worldwide epidemiology of psoriasis: systematic analysis and modelling study. *BMJ* **369**, m1590 (2020).
92. Elmet, C. A. et al. Joint AAD-NPF guidelines of care for the management and treatment of psoriasis with awareness and attention to comorbidities. *J. Am. Acad. Dermatol.* **80**, 1073–1113 (2019).
93. Takeshita, J. et al. Psoriasis and comorbid diseases: implications for management. *J. Am. Acad. Dermatol.* **76**, 393–403 (2017).
94. Takeshita, J. et al. Psoriasis and comorbid diseases: epidemiology. *J. Am. Acad. Dermatol.* **76**, 377–390 (2017).
95. Gelfand, J. M. et al. Risk of myocardial infarction in patients with psoriasis. *JAMA* **296**, 1735–1741 (2006).
96. Ogdie, A. et al. Risk of incident liver disease in patients with psoriasis, psoriatic arthritis, and rheumatoid arthritis: a population-based study. *J. Invest. Dermatol.* **138**, 760–767 (2018).
97. Mehta, N. N. et al. Patients with severe psoriasis are at increased risk of cardiovascular mortality: cohort study using the General Practice Research Database. *Eur. Heart J.* **31**, 1000–1006 (2010).
98. Wan, J. et al. Risk of moderate to advanced kidney disease in patients with psoriasis: population based cohort study. *BMJ* **347**, f5961 (2013).
99. Naik, H. B. et al. Severity of psoriasis associates with aortic vascular inflammation detected by FDG PET/CT and neutrophil activation in a prospective observational study. *Arterioscler. Thromb. Vasc. Biol.* **35**, 2667–2676 (2015).
100. Lerman, J. B. et al. Coronary plaque characterization in psoriasis reveals high-risk features that improve after treatment in a prospective observational study. *Circulation* **136**, 263–276 (2017).
101. Langan, S. M. et al. Psoriasis is associated with an increased prevalence of metabolic syndrome that varies directly with objectively measured severity. *J. Invest. Dermatol.* **131**, S82 (2011).
102. Mehta, N. N. et al. Abnormal lipoprotein particles and cholesterol efflux capacity in patients with psoriasis. *Atherosclerosis* **224**, 218–221 (2012).
103. Choi, H. et al. Treatment of psoriasis with biologic therapy is associated with improvement of coronary artery plaque lipid-rich necrotic core: results from a prospective, observational study. *Circ. Cardiovasc. Imaging* **13**, e011199 (2020).
104. Abuabara, K. et al. Cause-specific mortality in patients with severe psoriasis: a population-based cohort study in the U.K. *Br. J. Dermatol.* **163**, 586–592 (2010).
105. Gelfand, J. M. et al. The risk of mortality in patients with psoriasis: results from a population-based study. *Arch. Dermatol.* **143**, 1493–1499 (2007).
106. Sbidian, E. et al. Respiratory virus infection triggers acute psoriasis flares across different clinical subtypes and genetic backgrounds. *Br. J. Dermatol.* **181**, 1304–1306 (2019).
107. Jin, J. Q. et al. Mendelian randomization studies in psoriasis and psoriatic arthritis: a systematic review. *J. Invest. Dermatol.* **143**, 762–776.e3 (2023).
108. Patrick, M. T. et al. Shared genetic risk factors and causal association between psoriasis and coronary artery disease. *Nat. Commun.* **13**, 6565 (2022).
109. Rutsch, F. et al. A specific *IFIH1* gain-of-function mutation causes Singleton–Merten syndrome. *Am. J. Hum. Genet.* **96**, 275–282 (2015).
110. Bui, A. et al. The role of genetics on psoriasis susceptibility, comorbidities, and treatment response. *Dermatol. Clin.* **42**, 439–469 (2024).
111. Rutsch, F., Buers, I. & Nitschke, Y. Hereditary disorders of cardiovascular calcification. *Arterioscler. Thromb. Vasc. Biol.* **41**, 35–47 (2021).
112. Navrazhina, K. et al. The inflammatory proteome of hidradenitis suppurativa skin is more expansive than that of psoriasis vulgaris. *J. Am. Acad. Dermatol.* **86**, 322–330 (2022).
113. Garshick, M. S. et al. Inflammation signaling and impaired vascular health in psoriasis. *Arterioscler. Thromb. Vasc. Biol.* **39**, 787–798 (2019).
114. Mehta, N. N. et al. IFN- $\gamma$  and TNF- $\alpha$  synergism may provide a link between psoriasis and inflammatory atherogenesis. *Sci. Rep.* **7**, 13831 (2017).
115. Hawkes, J. E., Chan, T. C. & Krueger, J. G. Psoriasis pathogenesis and the development of novel targeted immune therapies. *J. Allergy Clin. Immunol.* **140**, 645–653 (2017).
116. Garshick, M. S. et al. An inflammatory transcriptomic signature in psoriasis associates with future cardiovascular events. *J. Eur. Acad. Dermatol. Venereol.* **37**, 1361–1365 (2023).
117. Gong, F. et al. The paradoxical role of IL-17 in atherosclerosis. *Cell. Immunol.* **297**, 33–39 (2015).
118. Garshick, M. S. et al. Activated platelets induce endothelial cell inflammatory response in psoriasis via COX-1. *Arterioscler. Thromb. Vasc. Biol.* **40**, 1340–1351 (2020).
119. Teague, H. L. et al. Neutrophil subsets, platelets, and vascular disease in psoriasis. *JACC Basic. Transl. Sci.* **4**, 1–14 (2019).
120. Yalcinkaya, M. et al. Cholesterol accumulation in macrophages drives NETosis in atherosclerotic plaques via IL-1 $\beta$  secretion. *Cardiovasc. Res.* **119**, 969–981 (2023).
121. Sorokin, A. V. et al. Bioactive lipid mediator profiles in human psoriasis skin and blood. *J. Invest. Dermatol.* **138**, 1518–1528 (2018).
122. Sorokin, A. V. et al. Association between oxidation-modified lipoproteins and coronary plaque in psoriasis. *Circ. Res.* **123**, 1244–1254 (2018).
123. Nakamura, Y. et al. Increased LL37 in psoriasis and other inflammatory disorders promotes LDL uptake and atherosclerosis. *J. Clin. Invest.* **134**, e172578 (2024).
124. Rivers, J. P. et al. Visceral adiposity in psoriasis is associated with vascular inflammation by <sup>18</sup>F-fluorodeoxyglucose positron-emission tomography/computed tomography beyond cardiometabolic disease risk factors in an observational cohort study. *JACC Cardiovasc. Imaging* **11**, 349–357 (2018).
125. Blake, T. et al. More than skin-deep: visceral fat is strongly associated with disease activity, function and metabolic indices in psoriatic disease. *Arthritis Res. Ther.* **25**, 108 (2023).
126. Papagrigoriaki, A. et al. Advanced glycation end products are increased in the skin and blood of patients with severe psoriasis. *Acta Derm. Venereol.* **97**, 782–787 (2017).
127. Greve, A. M., Wulff, A. B., Bojesen, S. E. & Nordestgaard, B. G. Elevated plasma triglycerides increase risk of psoriasis: a cohort and Mendelian randomization study. *Br. J. Dermatol.* **191**, 209–215 (2024).
128. Zhang, Y. et al. Updated evidence of the association between elevated serum uric acid level and psoriasis. *Front. Med.* **8**, 645550 (2021).



129. Zhan, H. et al. Association of circulating vascular endothelial growth factor levels with autoimmune diseases: a systematic review and meta-analysis. *Front. Immunol.* **12**, 674343 (2021).
130. Piepoli, M. F. et al. 2016 European Guidelines on cardiovascular disease prevention in clinical practice: The Sixth Joint Task Force of the European Society of Cardiology and Other Societies on Cardiovascular Disease Prevention in Clinical Practice (constituted by representatives of 10 societies and by invited experts). Developed with the special contribution of the European Association for Cardiovascular Prevention & Rehabilitation (EACPR). *Eur. Heart J.* **37**, 2315–2381 (2016).
131. Dauden, E. et al. Position statement for the management of comorbidities in psoriasis. *J. Eur. Acad. Dermatol. Venereol.* **32**, 2058–2073 (2018).
132. Chi, C. C. et al. 2022 Taiwanese Dermatological Association (TDA), Taiwanese Association for Psoriasis and Skin Immunology (TAPSI), and Taiwan Society of Cardiology (TSOC) joint consensus recommendations for the management of psoriatic disease with attention to cardiovascular comorbidities. *J. Formos. Med. Assoc.* **122**, 442–457 (2023).
133. National Institute for Health and Care Excellence. Psoriasis: assessment and management. NICE [www.nice.org.uk/guidance/CG153/](http://www.nice.org.uk/guidance/CG153/) (2017).
134. Song, W. B. et al. Regional variation in cardiovascular risk factor screening by dermatologists for psoriasis patients in the United States. *J. Invest. Dermatol.* **143**, 1816–1819 (2023).
135. Rutter, M. K. et al. Primary care-based screening for cardiovascular risk factors in patients with psoriasis. *Br. J. Dermatol.* **175**, 348–356 (2016).
136. Kimball, A. B. et al. Underdiagnosis and undertreatment of cardiovascular risk factors in patients with moderate to severe psoriasis. *J. Am. Acad. Dermatol.* **67**, 76–85 (2012).
137. Song, W. B. et al. A care coordination model to prevent cardiovascular events in patients with psoriatic disease: a multicenter pilot study. *J. Invest. Dermatol.* **144**, 1405–1409.e1 (2024).
138. Gelfand, J. M. et al. Association of apremilast with vascular inflammation and cardiometabolic function in patients with psoriasis: the VIP-A phase 4, open-label, nonrandomized clinical trial. *JAMA Dermatol.* **158**, 1394–1403 (2022).
139. Menter, A. et al. Joint American Academy of Dermatology-National Psoriasis Foundation guidelines of care for the management of psoriasis with systemic nonbiologic therapies. *J. Am. Acad. Dermatol.* **82**, 1445–1486 (2020).
140. Wiggins, B. S. et al. Recommendations for management of clinically significant drug–drug interactions with statins and select agents used in patients with cardiovascular disease: a scientific statement from the American Heart Association. *Circulation* **134**, e468–e495 (2016).
141. Nelson, K., Fuster, V. & Ridker, P. M. Low-dose colchicine for secondary prevention of coronary artery disease: JACC review topic of the week. *J. Am. Coll. Cardiol.* **82**, 648–660 (2023).
142. Dommasch, E. D., Troxel, A. B. & Gelfand, J. M. Major cardiovascular events associated with anti-IL 12/23 agents: a tale of two meta-analyses. *J. Am. Acad. Dermatol.* **68**, 863–865 (2013).
143. Poizeau, F. et al. Association between early severe cardiovascular events and the initiation of treatment with the anti-interleukin 12/23p40 antibody ustekinumab. *JAMA Dermatol.* **156**, 1208–1215 (2020).
144. Gelfand, J. M., Dommasch, E. D. & Mehta, N. N. Association between early severe cardiovascular events and ustekinumab treatment? *JAMA Dermatol.* **157**, 123 (2021).
145. Lee, M. P. et al. Association of ustekinumab vs TNF inhibitor therapy with risk of atrial fibrillation and cardiovascular events in patients with psoriasis or psoriatic arthritis. *JAMA Dermatol.* **155**, 700–707 (2019).
146. Reich, K. et al. Cardiovascular safety of ustekinumab in patients with moderate to severe psoriasis: results of integrated analyses of data from phase II and III clinical studies. *Br. J. Dermatol.* **164**, 862–872 (2011).
147. Rungapiromman, W. et al. Risk of major cardiovascular events in patients with psoriasis receiving biologic therapies: a prospective cohort study. *J. Eur. Acad. Dermatol. Venereol.* **34**, 769–778 (2020).
148. Gelfand, J. M. et al. A phase IV, randomized, double-blind, placebo-controlled crossover study of the effects of ustekinumab on vascular inflammation in psoriasis (the VIP-U trial). *J. Invest. Dermatol.* **140**, 85–93.e2 (2020).
149. European Medicines Agency. Summary of Product Characteristics: Stelara (INN ustekinumab). EMA [www.ema.europa.eu/en/documents/product-information/stelara-epar-product-information\\_en.pdf](http://www.ema.europa.eu/en/documents/product-information/stelara-epar-product-information_en.pdf) (2013).
150. Food and Drug Administration. FDA requires warnings about increased risk of serious heart-related events, cancer, blood clots, and death for JAK inhibitors that treat certain chronic inflammatory conditions. FDA [www.fda.gov/media/151936/download?attachment](http://www.fda.gov/media/151936/download?attachment) (2021).
151. European Medicines Agency. EMA confirms measures to minimise risk of serious side effects with Janus kinase inhibitors for chronic inflammatory disorders. EMA [www.ema.europa.eu/en/documents/referral/janus-kinase-inhibitors-jaki-article-20-procedure-ema-confirms-measures-minimise-risk-serious-side-effects-janus-kinase-inhibitors-chronic-inflammatory-disorders\\_en.pdf](http://www.ema.europa.eu/en/documents/referral/janus-kinase-inhibitors-jaki-article-20-procedure-ema-confirms-measures-minimise-risk-serious-side-effects-janus-kinase-inhibitors-chronic-inflammatory-disorders_en.pdf) (2023).
152. Medicines and Healthcare Products Regulatory Agency. Janus kinase (JAK) inhibitors: new measures to reduce risks of major cardiovascular events, malignancy, venous thromboembolism, serious infections and increased mortality. GOV.UK [www.gov.uk/drug-safety-update/janus-kinase-jak-inhibitors-new-measures-to-reduce-risks-of-major-cardiovascular-events-malignancy-venous-thromboembolism-serious-infections-and-increased-mortality](http://www.gov.uk/drug-safety-update/janus-kinase-jak-inhibitors-new-measures-to-reduce-risks-of-major-cardiovascular-events-malignancy-venous-thromboembolism-serious-infections-and-increased-mortality) (2023).
153. Ytterberg, S. R. et al. Cardiovascular and cancer risk with tofacitinib in rheumatoid arthritis. *N. Engl. J. Med.* **386**, 316–326 (2022).
154. Ingrassia, J. P. et al. Cardiovascular and venous thromboembolic risk with JAK inhibitors in immune-mediated inflammatory skin diseases: a systematic review and meta-analysis. *JAMA Dermatol.* **160**, 28–36 (2023).
155. Li, N. et al. Effect of JAK inhibitors on high- and low-density lipoprotein in patients with rheumatoid arthritis: a systematic review and network meta-analysis. *Clin. Rheumatol.* **41**, 677–688 (2022).
156. Ridker, P. M. et al. Low-dose methotrexate for the prevention of atherosclerotic events. *N. Engl. J. Med.* **380**, 752–762 (2019).
157. Goodwin Cartwright, B. M. et al. Changes in minoxidil prescribing after media attention about oral use for hair loss. *JAMA Netw. Open.* **6**, e2312477 (2023).
158. Vano-Galvan, S. et al. Safety of low-dose oral minoxidil for hair loss: a multicenter study of 1404 patients. *J. Am. Acad. Dermatol.* **84**, 1644–1651 (2021).
159. Sharma, A. N., Michelle, L., Juhasz, M., Muller Ramos, P. & Atanaskova Mesinkovska, N. Low-dose oral minoxidil as treatment for non-scarring alopecia: a systematic review. *Int. J. Dermatol.* **59**, 1013–1019 (2020).
160. Food and Drug Administration. Loniten (minoxidil tablets, USP). FDA [www.accessdata.fda.gov/drugsatfda\\_docs/label/2015/018154s026lbl.pdf](http://www.accessdata.fda.gov/drugsatfda_docs/label/2015/018154s026lbl.pdf) (2015).
161. Lilley, J. S., Linton, M. F. & Fazio, S. Oral retinoids and plasma lipids. *Dermatol. Ther.* **26**, 404–410 (2013).
162. Alcalay, J., Landau, M. & Zucker, A. Analysis of laboratory data in acne patients treated with isotretinoin: is there really a need to perform routine laboratory tests? *J. Dermatol. Treat.* **12**, 9–12 (2001).
163. Duvic, M. et al. Phase 2 and 3 clinical trial of oral bexarotene (Targretin capsules) for the treatment of refractory or persistent early-stage cutaneous T-cell lymphoma. *Arch. Dermatol.* **137**, 581–593 (2001).
164. Chung, E. S. et al. Randomized, double-blind, placebo-controlled, pilot trial of infliximab, a chimeric monoclonal antibody to tumor necrosis factor- $\alpha$ , in patients with moderate-to-severe heart failure: results of the anti-TNF Therapy Against Congestive Heart Failure (ATTACH) trial. *Circulation* **107**, 3133–3140 (2003).
165. Mann, D. L. et al. Targeted anticytokine therapy in patients with chronic heart failure: results of the Randomized Etorcept Worldwide Evaluation (RENEWAL). *Circulation* **109**, 1594–1602 (2004).
166. Roubille, C. et al. The effects of tumour necrosis factor inhibitors, methotrexate, non-steroidal anti-inflammatory drugs and corticosteroids on cardiovascular events in rheumatoid arthritis, psoriasis and psoriatic arthritis: a systematic review and meta-analysis. *Ann. Rheum. Dis.* **74**, 480–489 (2015).
167. Yang, Z. S., Lin, N. N., Li, L. & Li, Y. The effect of TNF inhibitors on cardiovascular events in psoriasis and psoriatic arthritis: an updated meta-analysis. *Clin. Rev. Allergy Immunol.* **51**, 240–247 (2016).
168. Gonzalez-Cantero, A. et al. Impact of biological agents on imaging and biomarkers of cardiovascular disease in patients with psoriasis: a systematic review and meta-analysis of randomized placebo-controlled trials. *J. Invest. Dermatol.* **141**, 2402–2411 (2021).
169. Mehta, N. N. et al. Effect of 2 psoriasis treatments on vascular inflammation and novel inflammatory cardiovascular biomarkers: a randomized placebo-controlled trial. *Circ. Cardiovasc. Imaging* **11**, e007394 (2018).
170. Weller, R. B. et al. The effect of daily UVA phototherapy for 2 weeks on clinic and 24-h blood pressure in individuals with mild hypertension. *J. Hum. Hypertens.* **37**, 548–553 (2023).
171. Aguilar, M. et al. Sun exposure and intima–media thickness in the Mexican Teachers’ Cohort Study. *J. Women’s Health* **32**, 366–374 (2023).
172. Weller, R. B. Sunlight has cardiovascular benefits independently of vitamin D. *Blood Purif.* **41**, 130–134 (2016).
173. Yang, S. et al. Association between sun-protective behaviors and hypertension: a cross-sectional study from National Health and Nutrition Examination Survey 2009 to 2014. *BMC Public. Health* **23**, 1862 (2023).
174. Kong, A. S. et al. Acanthosis nigricans: high prevalence and association with diabetes in a practice-based research network consortium – a PRImary care Multi-Ethnic network (PRIME Net) study. *J. Am. Board. Fam. Med.* **23**, 476–485 (2010).
175. Kong, A. S. et al. Acanthosis nigricans and diabetes risk factors: prevalence in young persons seen in southwestern US primary care practices. *Ann. Fam. Med.* **5**, 202–208 (2007).
176. Caceres, M., Teran, C. G., Rodriguez, S. & Medina, M. Prevalence of insulin resistance and its association with metabolic syndrome criteria among Bolivian children and adolescents with obesity. *BMC Pediatr.* **8**, 31 (2008).
177. Das, A. et al. Acanthosis nigricans: a review. *J. Cosmet. Dermatol.* **19**, 1857–1865 (2020).
178. Mourad, A. I. & Haber, R. M. Drug-induced acanthosis nigricans: a systematic review and new classification. *Dermatol. Ther.* **34**, e14794 (2021).
179. Nigwekar, S. U., Thadhani, R. & Brandenburg, V. M. Calciophylaxis. *N. Engl. J. Med.* **378**, 1704–1714 (2018).
180. Altman, K. & Shinohara, M. Demographics, comorbid conditions, and outcomes of patients with nonuremic calciophylaxis. *JAMA Dermatol.* **155**, 251–252 (2019).
181. Dyer, J. A. in *Fitzpatrick’s Dermatology* 9th edn Ch. 72 (eds Kang, S. et al.) (McGraw-Hill, 2019).
182. Forrester, A. K. & Micheletti, R. G. in *Fitzpatrick’s Dermatology* 9th edn Ch. 133 (eds Kang, S. et al.) (McGraw-Hill, 2019).
183. Iolascon, A. et al. Recommendations for diagnosis and treatment of methemoglobinemia. *Am. J. Hematol.* **96**, 1666–1678 (2021).

184. Wieckowski, K., Gallina, T., Surdacki, A. & Chyrchel, B. Diagonal earlobe crease (Frank's sign) for diagnosis of coronary artery disease: a systematic review of diagnostic test accuracy studies. *J. Clin. Med.* **10**, 2799 (2021).
185. Wu, C., Yu, C., Yang, Y. & Jin, H. Heart failure in erythrodermic psoriasis: a retrospective study of 225 patients. *Front. Cardiovasc. Med.* **10**, 1169474 (2023).
186. Li, Q., Jiang, Q., Pfendner, E., Varadi, A. & Uitto, J. Pseudoxanthoma elasticum: clinical phenotypes, molecular genetics and putative pathomechanisms. *Exp. Dermatol.* **18**, 1–11 (2009).
187. Ueberham, L. et al. Pathophysiological gaps, diagnostic challenges, and uncertainties in cardiac sarcoidosis. *J. Am. Heart Assoc.* **12**, e027971 (2023).
188. Kassamali, B. et al. Increased risk of systemic and cardiac sarcoidosis in Black patients with cutaneous sarcoidosis. *J. Am. Acad. Dermatol.* **86**, 1178–1180 (2022).
189. Wu, J. H., Imadojemu, S. & Caplan, A. S. The evolving landscape of cutaneous sarcoidosis: pathogenic insight, clinical challenges, and new frontiers in therapy. *Am. J. Clin. Dermatol.* **23**, 499–514 (2022).
190. Elawad, O. & Albashir, A. D. Frank's sign: dermatological marker for coronary artery disease. *Oxf. Med. Case Rep.* **2021**, omab089 (2021).
191. Armstrong, A. W. et al. Psoriasis prevalence in adults in the United States. *JAMA Dermatol.* **157**, 940–946 (2021).
192. Kurd, S. K. & Gelfand, J. M. The prevalence of previously diagnosed and undiagnosed psoriasis in US adults: results from NHANES 2003–2004. *J. Am. Acad. Dermatol.* **60**, 218–224 (2009).
193. Silverberg, J. I. Public health burden and epidemiology of atopic dermatitis. *Dermatol. Clin.* **35**, 283–289 (2017).
194. Wan, J. et al. Incidence of cardiovascular disease and venous thromboembolism in patients with atopic dermatitis. *J. Allergy Clin. Immunol. Pract.* **11**, 3123–3132.e3 (2023).
195. Silverwood, R. J. et al. Atopic eczema in adulthood and mortality: UK population-based cohort study, 1998–2016. *J. Allergy Clin. Immunol.* **147**, 1753–1763 (2021).
196. Silverwood, R. J. et al. Severe and predominantly active atopic eczema in adulthood and long term risk of cardiovascular disease: population based cohort study. *BMJ* **361**, k1786 (2018).
197. Chen, T. L., Huang, W. T., Loh, C. H., Huang, H. K. & Chi, C. C. Risk of venous thromboembolism among adults with atopic dermatitis. *JAMA Dermatol.* **159**, 720–727 (2023).
198. Merola, J. F. et al. Venous thromboembolism risk is lower in patients with atopic dermatitis than other immune-mediated inflammatory diseases: a retrospective, observational, comparative cohort study using US claims data. *J. Am. Acad. Dermatol.* **90**, 935–944 (2023).
199. Schneeweiss, M. C. et al. Incidence of venous thromboembolism in patients with dermatologist-diagnosed chronic inflammatory skin diseases. *JAMA Dermatol.* **157**, 805–816 (2021).
200. Jfri, A. et al. Prevalence of hidradenitis suppurativa: a systematic review and meta-regression analysis. *JAMA Dermatol.* **157**, 924–931 (2021).
201. Goldburg, S. R., Strober, B. E. & Payette, M. J. Hidradenitis suppurativa: epidemiology, clinical presentation, and pathogenesis. *J. Am. Acad. Dermatol.* **82**, 1045–1058 (2020).
202. Egeberg, A., Gislason, G. H. & Hansen, P. R. Risk of major adverse cardiovascular events and all-cause mortality in patients with hidradenitis suppurativa. *JAMA Dermatol.* **152**, 429–434 (2016).
203. Hung, C. T. et al. Increased risk of cardiovascular comorbidities in hidradenitis suppurativa: a nationwide, population-based, cohort study in Taiwan. *J. Dermatol.* **46**, 867–873 (2019).
204. Gether, L., Overgaard, L. K., Egeberg, A. & Thyssen, J. P. Incidence and prevalence of rosacea: a systematic review and meta-analysis. *Br. J. Dermatol.* **179**, 282–289 (2018).
205. Li, Y. et al. Association between rosacea and cardiovascular diseases and related risk factors: a systematic review and meta-analysis. *Biomed. Res. Int.* **2020**, 7015249 (2020).
206. Choi, D., Choi, S., Choi, S., Park, S. M. & Yoon, H. S. Association of rosacea with cardiovascular disease: a retrospective cohort study. *J. Am. Heart Assoc.* **10**, e020671 (2021).
207. Mostaghimi, A. et al. Trends in prevalence and incidence of alopecia areata, alopecia totalis, and alopecia universalis among adults and children in a US employer-sponsored insured population. *JAMA Dermatol.* **159**, 411–418 (2023).
208. Ly, S. et al. Comorbid conditions associated with alopecia areata: a systematic review and meta-analysis. *Am. J. Clin. Dermatol.* **24**, 875–893 (2023).
209. Kim, M. W., Shin, I. S., Yoon, H. S., Cho, S. & Park, H. S. Lipid profile in patients with androgenetic alopecia: a meta-analysis. *J. Eur. Acad. Dermatol. Venereol.* **31**, 942–951 (2017).
210. Yamada, T., Hara, K., Umematsu, H. & Kadowaki, T. Male pattern baldness and its association with coronary heart disease: a meta-analysis. *BMJ Open.* **3**, e002537 (2013).
211. Zhao, S. S., Yiu, Z. Z. N., Barton, A. & Bowes, J. Association of lipid-lowering drugs with risk of psoriasis: a mendelian randomization study. *JAMA Dermatol.* **159**, 275–280 (2023).
212. Azfar, R. S. & Gelfand, J. M. Psoriasis and metabolic disease: epidemiology and pathophysiology. *Curr. Opin. Rheumatol.* **20**, 416–422 (2008).
213. Gao, N. et al. The association between psoriasis and risk of cardiovascular disease: a mendelian randomization analysis. *Front. Immunol.* **13**, 918224 (2022).

## Author contributions

The authors contributed substantially to all aspects of the article.

## Competing interests

J.M.G. has served as a consultant for and has received honoraria from Abbvie, Artax (Data Safety and Monitoring Board (DSMB)), BMS, Boehringer Ingelheim, Celldex (DSMB), FIDE (which is sponsored by multiple pharmaceutical companies), GSK, Inmagine (DSMB), Lilly, Leo, Moonlake (DSMB), Janssen Biologics, Neuroderm (DSMB), Novartis, UCB (DSMB) and Veolia North America; receives research grants (to the trustees of the University of Pennsylvania) from Amgen, BMS and Pfizer; received payment for continuing medical education work related to psoriasis that was supported indirectly by pharmaceutical sponsors; is a co-patent holder of resiquimod for the treatment of cutaneous T cell lymphoma; is a Deputy Editor for the *Journal of Investigative Dermatology*, receiving honoraria from the Society for Investigative Dermatology; is Chief Medical Editor for *Healio Dermatology* (receiving honoraria); and is a member of the Board of Directors for the International Psoriasis Council and the Medical Dermatology Society (receiving no honoraria). M.S.G. has received consultant fees from Agepha, BMS, Horizon Therapeutics and Kiniksa, has received research grant support from Pfizer, and is supported by an NIH NHLBI grant (K23HL152013). The other authors declare no competing interests.

## Additional information

**Peer review information** *Nature Reviews Cardiology* thanks Christopher Griffiths and the other, anonymous, reviewer(s) for their contribution to the peer review of this work.

**Publisher's note** Springer Nature remains neutral with regard to jurisdictional claims in published maps and institutional affiliations.

Springer Nature or its licensor (e.g. a society or other partner) holds exclusive rights to this article under a publishing agreement with the author(s) or other rightsholder(s); author self-archiving of the accepted manuscript version of this article is solely governed by the terms of such publishing agreement and applicable law.

© Springer Nature Limited 2024

<sup>1</sup>Department of Dermatology, Perelman School of Medicine, University of Pennsylvania, Philadelphia, PA, USA. <sup>2</sup>Department of Biostatistics, Epidemiology and Informatics, Perelman School of Medicine, University of Pennsylvania, Philadelphia, PA, USA. <sup>3</sup>Department of Non-communicable Disease Epidemiology, London School of Hygiene and Tropical Medicine, University of London, London, UK. <sup>4</sup>Leon H. Charney Division of Cardiology, Department of Medicine, NYU Grossman School of Medicine, New York City, NY, USA. <sup>5</sup>Ronald O. Perelman Department of Dermatology, NYU Grossman School of Medicine, New York City, NY, USA.